

# Mapping Early Brain Development in Autism

Eric Courchesne,<sup>1,2,\*</sup> Karen Pierce,<sup>1,2</sup> Cynthia M. Schumann,<sup>1,2</sup> Elizabeth Redcay,<sup>2,3</sup> Joseph A. Buckwalter,<sup>1,2</sup> Daniel P. Kennedy,<sup>1</sup> and John Morgan<sup>1,2</sup>

<sup>1</sup>Department of Neurosciences, School of Medicine, University of California, San Diego, La Jolla, CA 92093, USA

<sup>2</sup>Autism Center of Excellence, School of Medicine, University of California, San Diego, La Jolla, CA 92093, USA

<sup>3</sup>Department of Psychology, University of California, San Diego, La Jolla, CA 92093, USA

\*Correspondence: [ecourchesne@ucsd.edu](mailto:ecourchesne@ucsd.edu)

DOI 10.1016/j.neuron.2007.10.016

Although the neurobiology of autism has been studied for more than two decades, the majority of these studies have examined brain structure 10, 20, or more years after the onset of clinical symptoms. The pathological biology that causes autism remains unknown, but its signature is likely to be most evident during the first years of life when clinical symptoms are emerging. This review highlights neurobiological findings during the first years of life and emphasizes early brain overgrowth as a key factor in the pathobiology of autism. We speculate that excess neuron numbers may be one possible cause of early brain overgrowth and produce defects in neural patterning and wiring, with exuberant local and short-distance cortical interactions impeding the function of large-scale, long-distance interactions between brain regions. Because large-scale networks underlie socio-emotional and communication functions, such alterations in brain architecture could relate to the early clinical manifestations of autism. As such, autism may additionally provide unique insight into genetic and developmental processes that shape early neural wiring patterns and make possible higher-order social, emotional, and communication functions.

Autism is a genetic disorder of neural development in which the first behavioral symptoms appear early in life. It is more heritable than breast cancer, colon cancer, Alzheimer's disease, or schizophrenia. There may also be important differences in the genetic mechanisms in children with autism from multiplex families versus singleton children with no family history of autism (Sebat et al., 2007; Zhao et al., 2007). Nongenetic factors are thought to play a role in causing the disorder, but remain unidentified. Severe developmental delay and impairment occur in higher-order social, emotional, language, and communication functions (Lord and Risi, 2000; Rogers and Di Lalla, 1990). The first behavioral signs of autism may appear between 1 and 2 years of age and largely involve abnormalities in social attention, language development, and emotional reactivity (Landa and Garrett-Mayer, 2006; Wetherby et al., 2004; Zwaigenbaum et al., 2005), and the diagnosis of autism is commonly made by 2–4 years of age. Autism spectrum disorders (ASD; referred to as autism throughout this review) are relatively common, occurring in 1 out of 150 individuals (Fombonne, 2005). Treatment costs for a child can be as much \$30,000 per year, and the cost of autism in the US is estimated to be as much as \$35 billion per year (Ganz, 2007).

Perhaps the most startling statistic, however, is that for this disorder of neural development, there are very few studies of early neural anatomical development at the age of clinical onset, namely between 2 and 4. This age is a critical period for early intervention therapies. This is also the most important period in human life for the formation of the neural wiring patterns that make possible the

development of higher-order social, emotional, and communication functions, the very ones that are profoundly impaired in autism. Large-scale, long-distance connections between diverse brain regions make these important functions possible. The genetic and developmental processes that organize developing brain networks and presumably aid in disorganizing autistic brain networks are largely unstudied in the early developmental time period in humans. Thus, the original alterations in brain architecture that produce dysfunction in socio-emotional and communication networks in the infant and toddler with autism remain a mystery.

Instead, autism studies have largely focused on ages 10, 20, or more years after the onset of the disorder. For instance, of the nearly 100 magnetic resonance imaging (MRI), diffusion tensor imaging (DTI), and postmortem studies of brain structure in autism in the past decade, only six MRI, one DTI, and zero postmortem studies have specifically studied autistic children at the typical age of first clinical identification and diagnosis, namely 2–4 years. The only anatomical evidence at the age of first preclinical signs, namely 1–2 years, comes from several retrospective head circumference studies based on pediatric records. There is also not a single study of the early development of anatomical connections in autism. Although not a measure of connectivity patterns, the volume of cerebral white matter has been reported in three MRI studies in 2- to 4-year-old autistic children (Carper et al., 2002; Courchesne et al., 2001; Hazlett et al., 2005). The most interesting white matter evidence regarding possible connectivity abnormalities comes from one study

of 7- to 11-year-olds (Herbert et al., 2004; see below). Of the 39 postmortem studies of autism, the mean age of autistic cases is 21 years, an average of two decades after clinical onset.

Thus, a great percentage of the literature on autism anatomy has addressed the question of what anatomical abnormalities characterize the disorder 10, 20, or more years after clinical onset, but studies of the older and mature autistic brain leave unaddressed the question of what neural structural abnormalities underlie the emergence of autistic behavior in the beginning stages. Studies of early development are required to address that fundamental question, and, although few in number, new developmental studies have revealed the phenomenon of abnormal early brain overgrowth during the first years of life in this disorder. New theories based on this neurodevelopmental evidence argue for early malformation of neural circuits in specific higher-order cortices that mediate the social, emotional, language, and communication dysfunctions that are core features of the disorder.

These recent studies of early development are reviewed in depth below. However, these new developmental findings may be more vividly appreciated when placed into the larger context of MRI, DTI, and postmortem evidence on the adolescent or adult autistic brain. The following is a brief summary of that literature; for other reviews, see Bauman and Kemper, 2005; Cody et al., 2002; Courchesne et al., 2004; Courchesne and Pierce, 2005a; Herbert, 2005; Palmen et al., 2004.

### **Anatomic Evidence on the Autistic Brain 10–20 or More Years after Clinical Onset**

The overall picture from the postmortem literature on the older child or adult with autism starkly contrasts with what one might expect from early brain overgrowth. It is one of neuron loss, degeneration, inflammation, and reduced size of cortical minicolumns (the vertical organization of neurons in the neocortex). The largest postmortem study of autism to use stereological methods for quantifying neuron numbers in 10- to 44-year-old cases found fewer neurons in the amygdala, a structure important in emotion, learning, and memory (Schumann and Amaral, 2006). The cerebellum, a structure that is important for its role in modulating a variety of cognitive and motor functions, has been consistently reported to have reduced numbers of cerebellar Purkinje neurons, without which this structure does not function properly (Bailey et al., 1998; Kemper and Bauman, 1998; Lee et al., 2002; Vargas et al., 2005). One caveat is that the finding of Purkinje cell loss has yet to be confirmed with a quantitative stereological study. Interestingly, Bailey et al. (1998) observed astrogliosis, a sign of glial activation that may be associated with neuronal degeneration or death, in the cerebellum. Vargas et al. (2005) reported degenerating Purkinje neurons, glial activation, and increases in pro- and anti-inflammatory molecules in the cerebellum. Neurons in the deep cerebellar nuclei, the only pathway exiting the cerebellum, were reported to be abnormally small and pale in adoles-

cent and adult autistic cases (Kemper and Bauman, 1998). In frontal cortex, which mediates many higher-order functions, Araghi-Niknam and Fatemi (2003) found increases in proapoptotic (pro-cell death) and decreases in antiapoptotic (anti-cell death) molecules in adult autistic cases. Increased molecular signs of glial activation have also been reported in the cerebrum (Laurence and Fatemi, 2005). Vargas et al. (2005) reported glial activation and pro- and anti-inflammatory molecules in frontal cortex. Studies have also found smaller frontal and temporal cortical minicolumns in older children, adolescents, and adults with autism (Buxhoeveden et al., 2006; Casanova et al., 2002, 2006). Clearly, more information is needed on the possible pathology of dendrites, axons, myelin, synapses, and the numbers of cortical minicolumns and neurons at all ages in autism, but such studies have yet to be carried out.

Some evidence of possible degenerative processes in adults with autism and/or reduced anatomic size also comes from the *in vivo* imaging literature. Progressive, age-related degeneration in the autistic brain from childhood to adulthood was first described nearly 30 years ago by Hoshino et al. (Hoshino et al., 1984) from CT data, and nearly 15 years ago, a qualitative MRI study reported cortical thinning, sulcal widening, and occasionally ventricular enlargement in superior parietal and frontal regions (Courchesne et al., 1993). Most recently, Hadjikhani et al. (2006) provided a detailed cortical map showing abnormally thin cortices in multiple superior parietal, temporal, and frontal regions in adolescents with autism. Interestingly, these regions include the mirror neuron system, which has been hypothesized by some to be critical in autism (Dapretto et al., 2006; Hadjikhani et al., 2006; Oberman et al., 2005; Oberman and Ramachandran, 2007; Williams et al., 2001, 2006). Potentially consistent with this would be a new finding showing reduced frontal lobe volumes in adults with autism (Schmitz et al., 2007). On MRI, the amygdala in autism is reported to be either similar to (Schumann et al., 2004) or smaller than (Nacewicz et al., 2006; Pierce et al., 2004) normal adolescents and adults. The corpus callosum, which carries interhemispheric axons, has been consistently reported to have reduced size in one or another of its subregions (Alexander et al., 2007; Chung et al., 2004; Egaas et al., 1995; Hardan et al., 2000; Just et al., 2007; Manes et al., 1999). The cerebellar vermis, which may be involved in modulating emotion, arousal, and sensory responsiveness, has been reported to be similar to (Piven et al., 1992) or smaller than (Ciesielski et al., 1997; Courchesne et al., 1988, 1994, 2001; Kaufmann et al., 2003; Levitt et al., 1999) typically developing children, adolescents, and adults. However, not all MRI studies have found abnormally thin cortices in mature autistic subjects (Hardan et al., 2006); some have reported that cortical gray matter enlargement may persist into adolescence and adulthood (Hazlett et al., 2006; Lotspeich et al., 2004).

On the other hand, meta-analyses of all available MRI and postmortem data show that overall brain size is near

the normal average in autistic adolescents and adults, with differences from normal being only about 1% in volume or weight (Redcay and Courchesne, 2005). Despite the lack of significant brain weight difference, about 5% of adolescent and adult postmortem cases of autism do have exceptionally heavy brain weights (Courchesne et al., 1999; Redcay and Courchesne, 2005).

Head circumference (HC) findings in adolescents and adults with autism have also been reported. Unfortunately, HC is an imprecise measure of brain size in adults because, from adolescence onward, CSF occupies an increasing percentage of the volume inside the head, and the brain occupies a decreasing percentage (Bartholomeusz et al., 2002). In fact, research shows that despite slightly larger head circumference in older autistic patients, brain size is near the average of normal subjects (Aylward et al., 2002). These data suggest that HC is not necessarily an accurate index of the size of the brain within the head in adults and adolescents with autism.

According to the large amount of literature conducted 10, 20, or more years after the clinical onset of autism, the norm for patients is an average size brain overall. This “normalcy,” however, may belie pathological, possibly neuroinflammatory, processes in frontal, temporal, cerebellar, and amygdala regions that favor degeneration, neuron loss, and perhaps loss of connections, although this latter possibility is speculative. Variable volumetric findings across MRI studies may reflect individual variability in such pathological processes and their consequences for neuronal and circuit survival. Across most structures that were measured, the most common finding is average to smaller than normal volume. The relationships between the pathologies seen at postmortem and in vivo neural, behavioral, and clinical functioning can only be speculated at this time.

### Mature Compared to Developing Brain in Autism

How does evidence gleaned 10–20 years after clinical onset square with data on autism at the age of clinical onset? That is, at 2–4 years of age, is there reduced size of anatomical structures, loss of neurons, and reduced size of minicolumns? Is the brain normal in size? Is brain enlargement present in just a small 5% of autism cases, perhaps reflecting only a rare subtype of autism?

In fact, much of the adult literature does not square with new evidence on the young autistic brain. The overall picture from MRI and single case studies does not show loss, reduction, and possible decline, but instead excessive growth and size. MRI brain volume is 5%–12% greater than normal in very young autistic children compared to controls, not just the overall average of 1% found in meta-analyses of adolescent and adult autism patients (Courchesne et al., 2001; Hazlett et al., 2005; Redcay and Courchesne, 2005; Sparks et al., 2002). There are other examples in specific brain regions; for instance, Sparks et al. (2002) found a larger amygdala on MRI in living 4-year-old autistic children, not a smaller one as would be predicted based on the adult findings of reduced

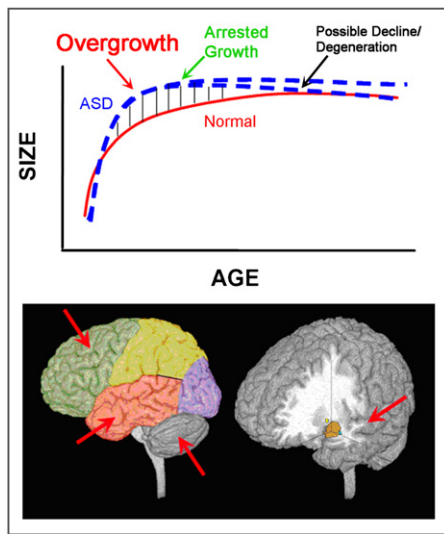
amygdala neuron numbers. Importantly, *enlargement* of the right amygdala in 3- and 4-year-old autistic children has been correlated with *increased* severity of social and communication scores on clinical tests (Munson et al., 2006), an intriguing finding considering the implicated social and emotional processing functions of the amygdala. We found normal average minicolumn size in a 3-year-old with autism, the youngest case ever studied in the postmortem literature, and not reduced size as would be predicted from the adult autism minicolumn literature (Buxhoeveden et al., 2006). Bailey et al. (1998) did not find Purkinje neuron loss in a 4-year-old autism case, in contrast to the adult autistic literature that finds Purkinje loss to be a consistent result. In the only published stereological study of frontal cortex neuron numbers, Kennedy et al. (2007) found 58% more spindle neurons, which are large specialized pyramidal cells thought by some to be important elements in social processing circuits, in a 3-year-old autistic case as compared to an age- and hemisphere-matched control. It should be noted that these findings are from a single patient and highlight the need for large-sample studies of frontal cortical neuron numbers in the young autistic brain.

Entirely unlike the adult picture, the picture in the very young autistic child that is now emerging is one of excess and enlargement, possibly in the very same regions that 10, 20, or more years later show pathological degeneration, loss, and size reduction. This has given rise to a new hypothesis: early brain development in autism is characterized by two phases of brain growth pathology (Courchesne et al., 2001, 2003; Courchesne and Pierce, 2005a): *early brain overgrowth* at the beginning of life and *slowing or arrest of growth* during early childhood (Figure 1). In some individuals, a third phase, *degeneration*, may be present in some brain regions by preadolescence. Pathological processes underlying these phases could be related because regions that undergo early overgrowth later undergo arrest of growth and, in some individuals, pathological degeneration with age. Age-related changes in structure as well as substantial heterogeneity in long-term outcome might alter or mask early brain pathology. Therefore, data from older ages may be useful in identifying potential regions of early abnormality but cannot directly inform the neurobiological beginnings of an aberrant developmental trajectory in autism.

### Early Brain Overgrowth in Autism

#### Evidence from Head Circumference and MRI Studies

During the first years of life, head circumference does correlate well with brain size in typically developing and autistic children (Bartholomeusz et al., 2002), and it has been used as a retrospective indicator of relative brain size in autism. At birth, head circumference in infants who later go on to develop autism is typically near normal or slightly below the normal average (Courchesne et al., 2003; Dawson et al., 2007; Dementieva et al., 2005; Dissanayake et al., 2006; Gillberg and de Souza, 2002; Hazlett et al.,




**Figure 1. Regional Early Overgrowth in ASD**

(A) Model of early brain overgrowth that is followed by arrest of growth. Blue lines represent ASD, while red lines represent age-matched typically developing individuals. In some regions and individuals, the arrest of growth may be followed by degeneration, indicated by the blue dashes that slope slightly downward.

(B) Sites of regional overgrowth in ASD include frontal and temporal cortices, cerebellum, and amygdala.

2005; Lainhart et al., 1997; Mason-Brothers et al., 1990; Stevenson et al., 1997) (Figure 2). In the two studies that provided individual data (Courchesne et al., 2003; Dementieva et al., 2005), 90%–95% of the neonates later diagnosed as autistic had average to slightly smaller than average HC at birth, and only about 5% had excessively large HC at birth (Figures 3A and 3B). However, Courchesne et al. (2003) recently discovered that by 1 or 2 years of age in autism, head circumference (HC) becomes abnormally enlarged (Figures 3A and 3C). This finding of early overgrowth has now been replicated by many independent research groups (Dementieva et al., 2005; Dissanayake et al., 2006; Hazlett et al., 2005; Dawson et al., 2007) (e.g., Figures 3B and 3D).

By the time children with autism reach 2–4 years of age, overall MRI brain volume is abnormally enlarged by about 10% relative to typically developing 2- to 4-year-olds (Carper et al., 2002; Courchesne et al., 2001; Hazlett et al., 2005; Sparks et al., 2002). Two more recent MRI studies have confirmed this finding of brain enlargement in young autistic children, with mean subject ages of 2.7 years (Hazlett et al., 2005) and 3.9 years (Sparks et al., 2002). A meta-analysis of all published MRI brain size data on children, adolescents, and adults through early 2005 showed that the period of greatest brain enlargement in autism is during the toddler years and early childhood (but it is important to note that even at older ages there remains an overall 1%–3% percent greater brain volume in autistic patients) (Figure 4A) (Redcay and Courchesne, 2005).



**Figure 2. Comparison of Seven Independent Studies of Head Circumference Measurements (cm) in Relation to Roche and CDC Scales**

References: 1, Mason-Brothers et al., 1990; 2, Lainhart et al., 1997; 3, Gillberg and de Souza, 2002; 4, Courchesne et al., 2003; 5, Stevenson et al., 1997; 6, Dementieva et al., 2005; 7, Courchesne et al., 2001.

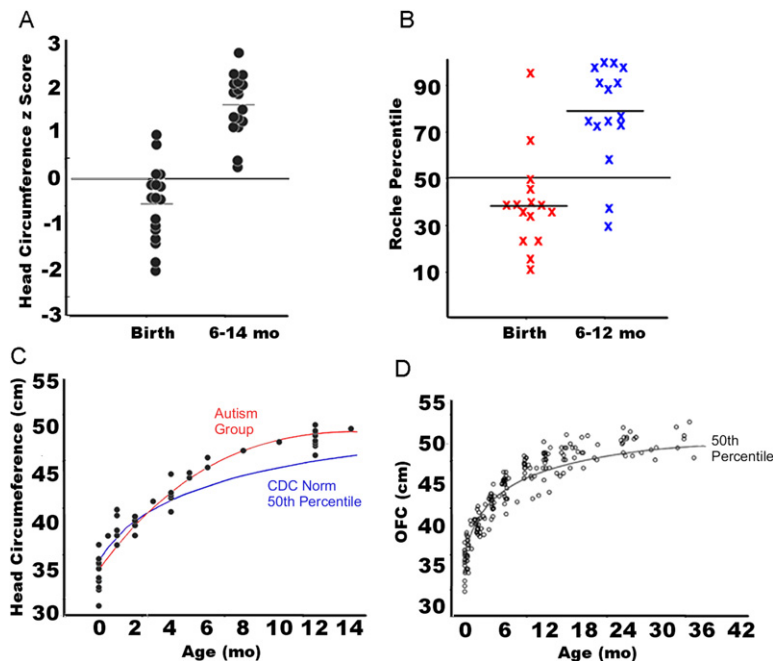
Postmortem brain weight data, although not necessarily always a reliable measure, does corroborate conclusions from HC and MRI studies. In the only study to statistically analyze age-related changes in autism brain weights, Redcay and Courchesne (2005) found that brain weight was 15% greater in 3- to 5-year-old male autism cases than male control cases (1451 g versus 1259 g) (see Figure 4B). Adult brains also have more cerebrospinal fluid, which may erroneously increase recorded brain weights. Even so, the difference between adults with autism and nonautistic control brains is diminished to about 1% (Figure 4B). It is important to note that the average brain weight of 1451 g in the 3- to 5-year-old autism cases is about the same as the average normal adult male brain (Courchesne et al., 1999).

#### Regions Showing Early Anatomic Overgrowth

As will be discussed below, research to date suggests that early overgrowth is not ubiquitous across the brain. By 2–4 years of age, some regions and structures display overgrowth while others do not (Carper and Courchesne, 2005; Carper et al., 2002; Sparks et al., 2002). While there are many possible explanations, one possibility is the relative timing of overgrowth and/or regional-specific genetic mechanisms that might be involved.

Regarding timing, it is possible that some regions have not been reported to display overgrowth during early or late childhood because those regions have a much earlier development. That is, some very early developing brain regions may in fact experience abnormally accelerated overgrowth, but prior to the ages investigated by past MRI studies, namely, prior to 2–4 years of age. Thus, it could be that some regions or structures may in fact be experiencing a subsequent arrest of growth during a time





**Figure 3. Early Brain Overgrowth during the First Years of Life in Autism**

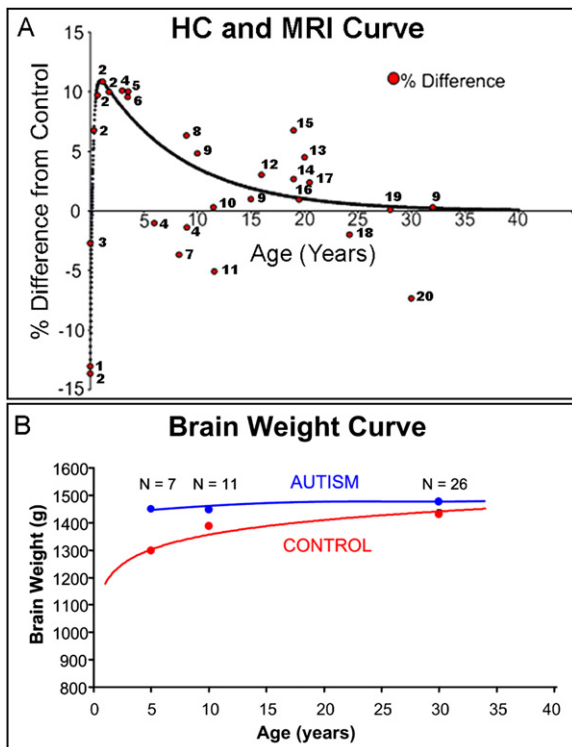
(A) Head circumference (HC) z-scores at birth and 6–14 months in individuals with autism relative to norms (from Courchesne et al., 2003) and (B) at 6–21 months of age (from Dementieva et al., 2005). (C and D) HC (cm) growth trajectory curves of autism subjects (red line in [C], open circles in [D]) compared to CDC 50th percentile (blue line in [C], black line in [D]), showing that neonates who later display autism undergo an abnormally accelerated rate of HC growth that becomes significantly larger than normal at 12 and 24 months of age (panel [C] from Courchesne et al., 2003; panel [D] from Dawson et al., 2007). Panels were adapted and reprinted with permission from Courchesne et al., 2003, Dementieva et al., 2005, and Dawson et al., 2007.

period when other later-developing systems are still experiencing overgrowth. Given this, it is important to point out that heterochronicity is a key variable in the proposed hypothesis of phases. Occipital cortex, for example, is an early developing region and, as discussed next, is one of the regions that show little or no evidence of overgrowth in studies of autistic children ages 2 years and up. Currently, there are no MRI studies of the autistic brain younger than 2–4 years of age, so occipital cortex, for example, may either not undergo overgrowth or overgrowth may occur prior to the age that MRI studies have considered.

With these considerations in mind, MRI research on autistic 2- to 4-year-olds implicates the frontal lobes, temporal lobes, and amygdala as sites of peak overgrowth (see Figure 1) (Carper and Courchesne, 2005; Carper et al., 2002; Courchesne et al., 2001; Hazlett et al., 2005; Sparks et al., 2002). Although gray and white matter volumes are substantially increased in the cerebrum as a whole (Courchesne et al., 2001; Hazlett et al., 2005), a striking finding across a number of studies and ages that reported gray matter volumes separately for each cerebral lobe is that frontal and temporal lobes are enlarged the most and occipital lobe the least (Bloss and Courchesne, 2007; Carper et al., 2002; Hazlett et al., 2006; Kates et al., 2004; Palmén et al., 2005) (see Figure 5). This regional gradient of abnormal enlargement parallels regions whose cognitive functions may be most impaired versus those most spared. In one study, frontal and temporal sulci are abnormally shifted anterior and/or superior in older autistic children (Levitt et al., 2003), which would be consistent with a disproportionate increase in frontal and temporal lobes.

It is reasonable to extrapolate that the same cerebral regions that experience the greatest amount of early overgrowth may also show the greatest white matter aberrations. Especially interesting is recent evidence of premature myelination in frontal, but not posterior, white matter regions in very young autistic children (Ben Bashat et al., 2007). A DTI study of autistic adolescents reported white matter abnormality underlying dorsal and medial prefrontal cortices, superior temporal cortex, temporoparietal junction, and the corpus callosum (Barnea-Goraly et al., 2004). In an MRI study of older autistic children and preadolescents, cerebral white matter was subdivided into internal and external compartments, and it was reported that the outer radiate portion of white matter, particularly in frontal lobes, was prominently disturbed; it was least deviant in occipital lobes (Herbert et al., 2004). This result suggests that autism might involve abnormal increases in short-distance connectivity, especially in brain regions that mediate higher-order language, cognitive, social, and emotional functions (see also Belmonte et al., 2004; Courchesne and Pierce, 2005b; Just et al., 2004). Conversely, decreases in the cross-sectional area of the callosum have been reported across a wide range of ages (Boger-Megiddo et al., 2006; Egaas et al., 1995; Just et al., 2007; Manes et al., 1999; Piven et al., 1997; Rice et al., 2005; Tsatsanis et al., 2003; Vidal et al., 2006). Because the majority of these studies were conducted in adolescents and adults, DTI and MRI volumetric studies of white matter in very young children with autism are needed to determine whether these abnormalities in the older child and adult with autism are consistent with the younger child.

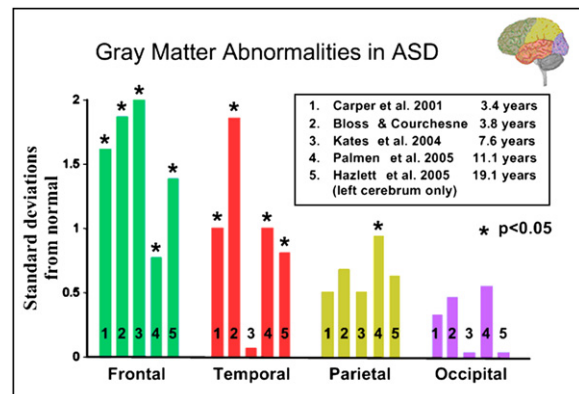
Thus, MRI studies of gray and white volume, cerebral sulci, and cerebral white matter development each point



**Figure 4. Brain Size Difference in Autism by Age**  
(A) Plot of a meta-analysis of 20 studies depicting brain size changes with age in ASD. Adapted with permission from Redcay and Courchesne, 2005.  
(B) Autism and control mean brain weight by age. Means of post-mortem brain weight values from individual autistic males and mean normative data were calculated for three age groups (3–5, 7–12, 13–70). Comparison of the two lines illustrates that while the normal brain continues to grow into adolescence, the autistic brain has already reached its near maximal weight by 3–5 years of age.  
References: 1, Gillberg and de Souza, 2002; 2, Courchesne et al., 2003; 3, Lainhart et al., 1997; 4, Courchesne et al., 2001; 5, Piven, 2004; 6, Sparks et al., 2002; 7, Kates et al., 2004; 8, Herbert et al., 2003; 9, Aylward et al., 2002; 10, McAlonan et al., 2005; 11, Rojas et al., 2005; 12, Shultz et al., 2005; 13, Palmen et al., 2005; 14, Hardan et al., 2003; 15, Piven et al., 1995; 16, Tsatsanis et al., 2003; 17, Aylward et al., 1999; 18, Carper, personal communication; 19, Haznedar et al., 2000; 20, Rojas et al., 2002.

to pronounced frontal and temporal lobe abnormality. Peak overgrowth pathology in the cerebrum in autism, therefore, appears to be in frontal and temporal lobes, regions that mediate the higher-order social, emotional, cognitive, and language functions that are impaired in this disorder. Studies are needed to determine whether these regional increases reflect an abnormally expanded cortical sheet, an abnormally thickened one, or both, as this information would suggest different forms of very early defects in corticogenesis.

The map of early cerebral anatomical abnormality is likely more complex than this because, within frontal cortex, some regions seem to be substantially enlarged (dorsolateral and mesial prefrontal), while others are enlarged less or not at all (orbital, precentral gyrus) (Carper and



**Figure 5. Summary of Observed Gray Matter Abnormalities (Standard Deviations from Normal) from Studies of Children and Adolescents with ASD**  
Note the general gradient of abnormality, with frontal and temporal regions most profoundly enlarged.  
References: 1, Carper et al., 2002; 2, Bloss and Courchesne, 2007; 3, Kates et al., 2004; 4, Palmen et al., 2005; 5, Hazlett et al., 2005.

Courchesne, 2005). Analyses of other cortical regions during early development have not been done, and the study of frontal regions did not examine subregions within the larger dorsal and mesial divisions. While subcortical structures have been less extensively studied than cortex, as noted above, the amygdala has also been reported to be enlarged in young (Sparks et al., 2002) as well as older (Schumann et al., 2004) children with autism. Thus, a complete regional map of early developmental overgrowth in the autistic brain remains to be charted.

### Early Brain Overgrowth and Abnormal Functional Activity

Early brain overgrowth occurs during developmentally critical years that are normally characterized by burgeoning language, social, emotion, and attention skills for the typically developing toddler, but strikingly deviant development for the infant and toddler with autism (Baron-Cohen et al., 1992; Landa and Garrett-Mayer, 2006; Wetherby et al., 2004; Zwaigenbaum et al., 2005). Therefore, a fundamental question is: *Are the neural systems that fail to provide those fundamental skills so early in neurobehavioral development also the ones that undergo abnormal overgrowth?* The answer remains unknown. The way the brain operates during this period of early overgrowth remains largely a mystery due to a paucity of studies.

To date, event-related potential (ERP) methods have been applied to the study of functional abnormalities in the very youngest autistic children. However, the neural systems underlying ERP abnormalities can only be speculated because anatomical localization is not a strength of ERPs. Nonetheless, the few existent ERP studies of 3- and 4-year-old autistic children report abnormal activity from electrodes over frontal and temporal scalp sites. Dawson et al. (2002) recorded ERP responses to familiar and unfamiliar social and nonsocial stimuli in autistic and normal

children. They found that in normal 3- to 4-year-old children, the P400 and frontal Nc components of the ERP were enhanced in amplitude in response to their mother's face as compared to a stranger's face and to a familiar toy as compared to an unfamiliar one. In contrast, autistic 3- to 4-year-olds did not show an enhanced response to their mother's face, but did to a familiar toy. In an elegant brain-behavior correlation study, Kuhl et al. (2005) showed that ERP responses to phoneme mismatches were more normal in autistic 2- to 4-year-olds who showed behavioral evidence of preference for "motherese" vocalizations over nonspeech sounds, but were more abnormal in autistic 2- to 4-year-olds who preferred the nonspeech sounds. These and other ERP studies by Dawson, Carver, Kuhl, and colleagues were the first to examine the electrophysiological correlates of impaired social and linguistic processing in autism during the first years of life (Carver and Dawson, 2002; Dawson et al., 2002, 2004; McPartland et al., 2004). Their studies support the general hypothesis that neurophysiological systems that mediate socially significant and meaningful information processing are more developmentally abnormal than those that mediate non-socially significant information processing, even when that non-social information is complex and personally relevant to the autistic toddler or young child.

The above ERP studies have given much needed information regarding neurobehavioral function in early autism; however, they only partially address the central question asked above, because ERPs remain unable to anatomically map dysfunction. To determine whether the specific neural systems undergoing overgrowth function abnormally in the autistic toddler, fMRI methods are needed because they provide a powerful noninvasive method for mapping cortical and subcortical brain functions. Until recently, however, fMRI has not been utilized for this purpose because it cannot be successfully used with awake, alert toddlers, whether autistic or typically developing. One possible solution is to conduct fMRI studies of autistic infants and toddlers during natural sleep. A number of ERP and fMRI studies comparing sleep and wake states across infants to adults suggest some higher-order cognitive processing, including differential processing of text passages, semantic incongruity, and one's own name, persists during natural sleep (Bastuji et al., 2002; Dehaene-Lambertz et al., 2002; Perrin et al., 1999, 2002; Wilke et al., 2003). Furthermore, infants show enhanced auditory discrimination abilities while awake to phonemes presented during sleep (Cheour et al., 2002). Thus, evidence suggests that during natural sleep the neural response to language, emotion, and other functions can be examined without incurring artifact due to motion. We have begun to conduct fMRI studies during natural sleep ([www.autismsandiego.com](http://www.autismsandiego.com)) and have demonstrated for the first time that it is possible to map the neural response to speech and nonspeech sounds as well as intrinsic functional networks in typically developing infants (Fransson et al., 2007) and toddlers (Redcay et al., 2007a, 2007b). While there are only a few studies that examine

auditory processing during sleep fMRI with infants and toddlers (Anderson et al., 2001; Dehaene-Lambertz et al., 2002; Redcay et al., 2007a, 2007b), we believe it to be a quite powerful method for revealing deviant neurofunctional systems early in development.

### Cellular and Molecular Bases of Overgrowth: Unknown

As discussed above, the cellular and molecular bases of pathological overgrowth in the young autistic brain are unknown. Further, the critical question of what age-related cellular and molecular changes occur between this time of early overgrowth and later maturity 10–20 or more years later has not been studied. Studies to date have been hampered by the low availability and quality of control as well as autistic brain tissue from younger cases. To understand the neural defects underlying the emergence of autism, it will be necessary for future research to use modern quantitative stereological methods to investigate the cellular basis of early brain overgrowth at the youngest ages in autism when the growth pathology is at its peak expression.

In the near absence of information that directs and constrains hypotheses, speculations have flourished. Among the numerous abnormalities that could create overgrowth in the young brain—but have yet to be examined by any study—are excess neuron numbers, excess glia, activated and enlarged glia, excess synapse numbers, excess numbers of minicolumns, excessive and premature axonal and/or dendritic growth, excessive and/or premature growth of neuron cell bodies, excess axon numbers, and excessive and/or premature myelination (see reviews by Bauman and Kemper, 2005; Palmen et al., 2004). Among the more prominent speculations has been that there are increased numbers of minicolumns in autism (Casanova et al., 2006). However, minicolumn numbers have not been stereologically quantified in either the child or adult autistic brain.

Recently, there has been speculation that the cause of autism is at the synapse (Garber, 2007), but in fact there have been no quantitative studies of any type of cortical synapse in the child with autism. Such speculations have come from genetic studies that have observed evidence of possible involvement of neuroligin and neurexin genes that affect synapse formation (Chubykin et al., 2005; Jamain et al., 2003), but it remains unclear whether the findings may speak to only a tiny percent of autism patients and how they would produce the gain of function that could explain early brain overgrowth. A small percentage of sporadic cases of autism have de novo copy number variations, typically in one gene within the genome (Sebat et al., 2007), but the link between those results and the dysregulation that leads to a brief period of excessive growth in early development in frontal, temporal, and amygdala regions is unclear. Important new findings are the association of the MET gene with autism in multiplex families and reduced expression levels of MET (Campbell et al., 2006) and members of its signaling pathway in

temporal lobe in postmortem autism studies (Campbell et al., 2007). However, reduction in MET expression would seem to predict reduced growth and neural circuit formation, making it unclear how this might relate to early brain overgrowth and excess gray and white matter volumes.

There are no gene-association studies of the early developmental phenotype of autism. It might be that the genes driving early developmental defects are not those that drive the *reaction* to those original developmental conditions. That is, causal and reactive genetic and nongenetic factors may be distinct. Thus, it remains an untested possibility that some portion of the heterogeneity of the autism phenotype reflects individual variation in genes and gene expression effects in response to pathological conditions set up during early development. Outcome variability may be shaped by variability in genes that must respond to earlier generated abnormal neural conditions. Thus, genotype-phenotype association studies that employ variation in brain size, gray matter volumes, immunological measures, functional activation patterns, language skills, social skills, or seizures in older children or adults with autism might be picking up relationships that reflect genetic factors that shape how each individual's nervous system responds to early developmental defect. It would seem possible that more powerful gene-association studies would utilize measures of the biological defects that are closest to the initial maldevelopment rather than defects that may be the long-term outcome of a long cascade of altered brain-gene expression-experience interactions.

For instance, suppose that one fundamental defect producing excess brain size is excess neurogenesis. Such an excess might trigger compensatory proapoptotic reactions aimed at correcting this excess, and individual variation in genes regulating such reactions might lead to variation in some patients having prolonged and/or profound proapoptotic activation while others might not. Genotype-phenotype studies using, for instance, mature brain size, amygdala size, or molecular markers of neuroinflammation might detect genes that influence variations in the proapoptotic reaction, and not genes that started the problem in the first place, namely genes that generated the abnormal excess number of neurons.

#### **What If: Excess Neurons and the Formation of Neural Connections**

One reasonable explanation for early overgrowth in autism is an excess of neuron numbers, particularly an excess of excitatory pyramidal neurons. Excess pyramidal neurons, which make up more than 80% of all neurons in the cortex, could potentially mean an excess of axons, dendrites, synapses, and myelin, and that would produce the enlarged volumes of gray and white matter as well as the overall enlarged brain volume reported in MRI studies of young autistic children (discussed above). Additionally, excess neurons could also mean increased brain weight in young autistic children. An increase in excitatory pyramidal neurons could produce an imbalance of excessive

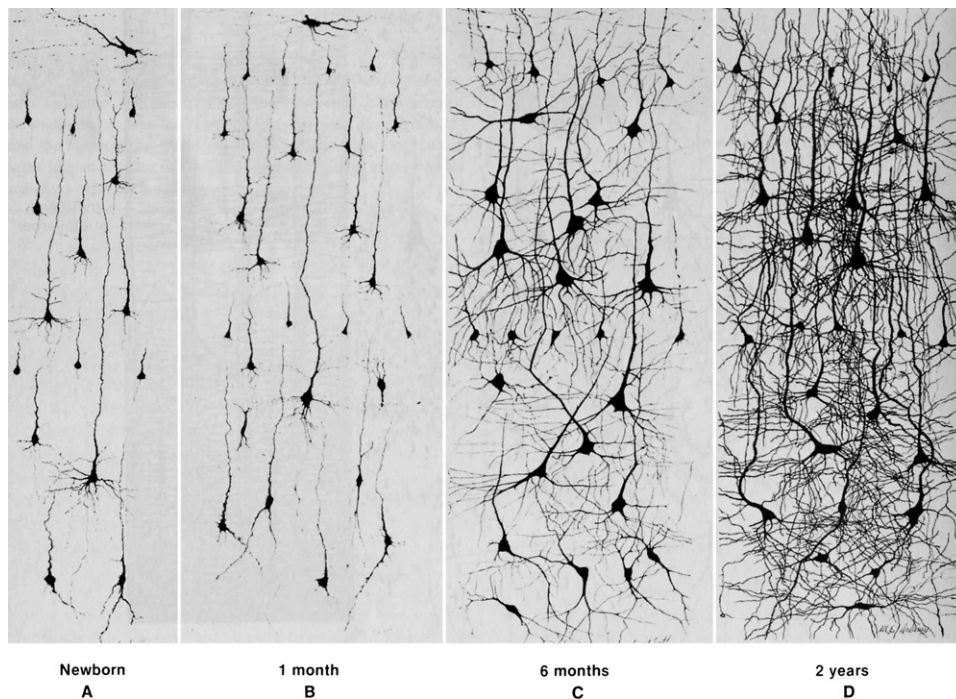
excitation relative to inhibition with its many adverse electrophysiological and behavioral consequences as so eloquently theorized by Rubenstein and Merzenich (Rubenstein and Merzenich, 2003). Such a mismatch in the ratio of excitatory to inhibitory neurons might tip the balance toward excessive and less controlled excitability, reduced selective responsiveness, spatially broad but disorganized cortical assemblies, and poorly synchronized volleys of signals from such excitable but diffuse and disorganized patches to lower-order systems (Courchesne and Pierce, 2005a).

Excess neuron numbers in early development seems an intuitively neat fit to the apparently proapoptotic neural environment in the mature brain (summarized above). Indeed, it may be that the most valuable clues to the causes of autism from the adult autistic postmortem literature are the findings that abnormal molecular, potentially neuroinflammatory, processes seem to be aimed at reducing neuron numbers. If such molecular processes are engaged at a relatively young age in autism, by 2–4 years of age perhaps, then arrest of macroscopic growth as described in MRI studies (reviewed above) becomes understandable, as does arrest of minicolumn growth in early childhood (also mentioned above).

An extreme excess of neurons in frontal and temporal cortices, where cerebral overgrowth is at its maximum according to MRI studies, could also explain why the first signs of autism begin between roughly 9 months and 2 years (and not typically later or much earlier) and involve lack of high-order language, social, emotional, and communication skills. It is during this developmental period that the formation of neural circuitry in these regions is most exuberant but also at its most vulnerable stage (Courchesne and Pierce, 2005a). In frontal cortex at birth, neurons are very small, dendritic arbors have barely sprouted, local and long-distance connections are sparse, and synapses are a fraction of their mature size and numbers (Conel, 1939, 1941, 1951, 1959; Huttenlocher, 2002), but this changes dramatically over the next 2 years (see Figure 6). The building of complex and intricate circuits in higher-order systems is a stunning feat of the infant and toddler brain, and within 18–24 months behavioral capacity has soared (Bates et al., 2003).

Excess neuron numbers could profoundly disrupt this major event of circuit formation in frontal and temporal cortices and thereby impede the emergence of higher-order behavior skills. For example, mismatches in the ratio of afferent axons from further noncortical sites to an excessively large pool of frontal and temporal cortical target neurons would produce broad, sporadic connectivity within the sites of innervation. Such disparate connectivity could potentially leave some neurons underinnervated and alter the afferent signals to these higher-order cortical regions. Resulting cortical “functional maps” would appear overall “normal,” but long-distance *functional* “interactions” would be weakened and noisy. This could explain one of the most consistent abnormalities reported in the adult autism literature, which is reduced long-distance





**Figure 6. Golgi-Stained Sections of Middle Frontal Gyrus Showing Growth of Pyramidal Neuron Soma and Dendrites**

The normal newborn has sparse neural circuitry, and then, with increasing age, there is a tremendous increase in the complexity of neural circuitry that is illustrated by the great increase of dendritic arbors from birth to 2 years. From Courchesne and Pierce (2005a), adapted from Nolte (1993), whose figure combined panels from Conel (1939, 1941, 1951, 1959).

functional connectivity between frontal and temporal higher cortices and between these cortices and other structures (Castelli et al., 2002; Cherkassky et al., 2006; Courchesne and Pierce, 2005b; Just et al., 2004, 2007; Kana et al., 2006; Koshino et al., 2007; Murias et al., 2007; Rippon et al., 2007; Villalobos et al., 2005).

Further, mismatches in the ratio of local intracortical or short-distance axons produced by excess neurons within higher-order systems relative to connections generated by other distant and low-level neural populations would lead to local and short-distance connections dominating numerically and functionally over long-distance afferent connections. In the process of activity-based competition, the numeric and signal-timing advantages of local and short-distance (and hyperexcitable) connections would easily win out over the inadequate numbers and timing of long-distance afferents. Such short-distance connections are in a so-called “radiate” white matter region immediately underlying cortex, and one MRI study of 7- to 11-year-old autistic subjects has reported volumes of this white matter to be excessive, with deviation from normal being greatest under frontal and temporal cortices (Herbert et al., 2004). Also, fMRI and EEG studies of functional connectivity in autism have consistently reported reduced long-distance functional connectivity, and from that, many have speculated that there might be reduced long-distance anatomical connectivity as well (Castelli et al., 2002; Cherkassky et al., 2006; Just et al., 2004, 2007; Kana

et al., 2006; Koshino et al., 2007; Mason et al., 2007; Murias et al., 2007; Rippon et al., 2007; Villalobos et al., 2005).

Perhaps most importantly, the imbalance of local and short-distance connectivity over long-distance connectivity would disrupt the formation and functioning of large-scale, long-distance assemblies. Such large-scale, long-distance networks include the mirror neuron system and the resting network, systems that involve frontal, temporal, and parietal cortices and mediate the sense of the physical and psychological self in relationship to physical and psychological actions and states of others (Frith and Frith, 2006; Iacoboni and Dapretto, 2006). The emergence and elaboration of these major physical and psychological social functions in autism are likely derailed by failure of large-scale, long-distance networks to operate.

The fundamental failure of such large-scale networks to form correctly may also be behind the failure of normal language acquisition in autistic toddlers. In our fMRI studies of 1- to 3-year-old typically developing toddlers, we observed functional activation patterns in response to language and concluded that the dramatic burst of language acquisition in normal toddlers depends on recruitment of large-scale networks involving frontal, temporal, occipital, and cerebellar regions (Redcay et al., 2007a). Studies in our laboratory with autistic toddlers are aimed at testing the theory that large-scale, long-distance networks fail to function in the young autistic brain for the reasons just given above.

Lastly, at a momentous period when it is vital to form large-scale networks out of the chaos of excess neurons and potentially poorly inhibited and organized short-distance connectivity, very early behavioral intervention could increase the chances that activity-dependent mechanisms could stabilize adaptive connections and eliminate nonadaptive ones. The interesting and hopeful view of this model is that higher-order systems and large-scale network connections may be present in autism, but stand at a disadvantage to the local overconnectivity and noise produced by the excess excitatory neurons.

In fact, new studies now show a remarkable effect: namely, extrinsic factors that serve to increase attention, motivation, or interest can cause more normal functional activation in brain regions and networks in high-functioning autistic individuals (Hadjikhani et al., 2004, 2007; Pierce et al., 2004; Wang et al., 2004, 2007). Examples of this phenomenon come primarily from the face-processing literature (Dalton et al., 2005; Hadjikhani et al., 2004; Pierce et al., 2004) and more recently during tasks of irony comprehension (Wang et al., 2007). Initial studies of face processing in autism revealed reduced or absent activity in the fusiform gyrus as compared to controls (Critchley et al., 2000; Pierce et al., 2001; Schultz et al., 2000). Recent research, however, has revealed that increasing interest or attention to the faces by showing familiar faces (Pierce et al., 2004) or increasing gaze fixation to the face by inserting a dot on the face and instructing subjects to attend to the face results in more normal fusiform activity (Hadjikhani et al., 2004, 2007). Indeed, Dalton et al. (2005) demonstrated that increased in attention to the eye region of the face is correlated with increased levels of fusiform and amygdala activity in autism. Similarly, during tasks of irony comprehension, typically developing children automatically engage medial frontal cortex, but children with autism do not do so unless specific instructions are given to attend to the facial expression or tone of voice (Wang et al., 2007). These series of studies support the position that local and long-distance networks can be activated in autism if sufficient instruction, motivation, or interest is given to the participant to overcome the natural tendency to not engage these regions. In other words, the *spontaneous activity* of the various local and long-distance networks is abnormally biased by the various mismatches mentioned above toward not automatically engaging in the presence of social-emotional cues. This raises the question of what conditions can overcome the threshold of this intrinsic and abnormal spontaneous activity. In this context, not enough can be said about how important it is to learn from those fMRI studies that *have* demonstrated conditions under which more normal functional activation and connectivity patterns can appear during the processing of faces (Dalton et al., 2005; Hadjikhani et al., 2004, 2007; Pierce et al., 2004; Wang et al., 2004). Such fMRI experiments with older autistic children and adults may point the way for social, emotional, and communication intervention

approaches with infants, toddlers, and young children at-risk for autism.

### Conclusions

New MRI and head circumference studies have given rise to a new hypothesis—autism involves two phases of early brain growth pathology (Courchesne et al., 2001, 2003; Courchesne and Pierce, 2005a): early *brain overgrowth* at the beginning of life and *slowing or arrest of growth* during early childhood (Figure 1). In some percentage of patients, a third phase, *degeneration*, may be present in some brain regions by preadolescence and continue into adulthood. This new theory of neural maldevelopment in autism highlights the first years of life as a key period when it appears that both malformation of neural circuitry is actively occurring *and* the first behavioral signs of autism are appearing (Landa and Garrett-Mayer, 2006; Wetherby et al., 2004; Zwaigenbaum et al., 2005). During the relatively brief and pivotal early period, the beginning steps in neural and behavioral maldevelopment in autism can be revealed as it occurs, rather than the outcome. The opportunity for discovering the underlying genetic and other factors that are driving maldevelopment may be at its maximum during this time. Genetic factors undoubtedly play a role in the early overgrowth pathology in autism, and their identification will have a major impact on understanding and treating those with the disorder. Knowledge of the defects and genetic or other factors involved will also likely reveal more specific and useful biomarkers of risk for autism, diagnostic outcome, and treatment responsiveness. Ultimately, it may lead to targeted modes of medical and behavioral treatment that greatly benefit functional outcome.

The neural defects that drive this overgrowth remain unknown. Therefore, studies of the underlying neural defects causing early brain overgrowth in autism are of the utmost importance. It must be assumed that more than one major underlying developmental neural defect drives this complex behavioral disorder.

In this paper, we propose the hypothesis that one such defect is an excess of neurons (and their axonal and dendritic processes and synapses) in key frontal and temporal cortical regions that mediate higher-order social communication, emotion, and language functions. By out-competing afferents from distant regions for synaptic space, diluting the impact of signals from distant brain regions, and generating excessive local excitation, excess neuron numbers may generate exuberant local intracortical and short-distance cortico-cortical interactions that impede the function of large-scale, long-distance interactions between brain regions. Because large-scale frontal, temporal, parietal, and subcortical networks underlie socio-emotional and communication functions, such alterations in brain architecture could relate to the early clinical manifestations in autism. In autism, then, excess local, but disordered, maps may win out over global representational maps, thereby skewing the kind of information most readily attended to, processed, and acted upon.

Evidence and this model nonetheless indicate that large-scale socio-emotional and language networks can be engaged in many autistic individuals, albeit with greater than normal difficulty. Though strongly skewed away from being spontaneously prepared to attend, process, and react to social information, the diminished functional coherence in such networks may not preclude effective activation, particularly in individuals with less excess of neurons. The challenge then is to identify at-risk infants and toddlers and start them on treatment protocols that maximally engage and reinforce the functioning of these critical large-scale networks. Neurobiological studies of autism in the first years of life offer great hope for making progress in understanding how early neural patterning abnormalities at the local and global level of organization arise and what biological as well as behavioral interventions may improve developmental outcome.

#### ACKNOWLEDGMENTS

This work was supported by NIMH grant 1P50MH081755-01 and NIMH grant 2-ROI-MH36840 awarded to E.C.

#### REFERENCES

Alexander, A.L., Lee, J.E., Lazar, M., Boudos, R., DuBray, M.B., Oakes, T.R., Miller, J.N., Lu, J., Jeong, E.K., McMahon, W.M., et al. (2007). Diffusion tensor imaging of the corpus callosum in Autism. *Neuroimage* 34, 61–73.

Anderson, A.W., Marois, R., Colson, E.R., Peterson, B.S., Duncan, C.C., Ehrenkranz, R.A., Schneider, K.C., Gore, J.C., and Ment, L.R. (2001). Neonatal auditory activation detected by functional magnetic resonance imaging. *Magn. Reson. Imaging* 19, 1–5.

Araghi-Niknam, M., and Fatemi, S.H. (2003). Levels of Bcl-2 and P53 are altered in superior frontal and cerebellar cortices of autistic subjects. *Cell. Mol. Neurobiol.* 23, 945–952.

Aylward, E., Minshew, N., Goldstein, G., Honeycutt, N., Augustine, A., Yates, K., Barta, P., and Pearlson, G. (1999). MRI volumes of amygdala and hippocampus in non-mentally retarded autistic adolescents and adults. *Neurology* 53, 2145–2150.

Aylward, E.H., Minshew, N.J., Field, K., Sparks, B.F., and Singh, N. (2002). Effects of age on brain volume and head circumference in autism. *Neurology* 59, 175–183.

Bailey, A., Luthert, P., Dean, A., Harding, B., Janota, I., Montgomery, M., Rutter, M., and Lantos, P. (1998). A clinicopathological study of autism. *Brain* 121, 889–905.

Barnea-Goraly, N., Kwon, H., Menon, V., Eliez, S., Lotspeich, L., and Reiss, A.L. (2004). White matter structure in autism: preliminary evidence from diffusion tensor imaging. *Biol. Psychiatry* 55, 323–326.

Baron-Cohen, S., Allen, J., and Gillberg, C. (1992). Can autism be detected at 18 months? The needle, the haystack, and the CHAT. *Br. J. Psychiatry* 161, 839–843.

Bartholomeusz, H.H., Courchesne, E., and Karns, C. (2002). Relationship between head circumference and brain volume in healthy normal toddlers, children, and adults. *Neuropediatrics* 33, 239–241.

Bastuji, H., Perrin, F., and Garcia-Larrea, L. (2002). Semantic analysis of auditory input during sleep: studies with event related potentials. *Int. J. Psychophysiol.* 46, 243–255.

Bates, E., Thal, D., Finlay, B., and Clancy, B. (2003). Early language development and its neural correlates. In *Child Neuropsychology*,

Part II, S.J. Segalowitz and I. Rapin, eds. (New York: Elsevier), pp. 525–592.

Bauman, M.L., and Kemper, T.L. (2005). Neuroanatomic observations of the brain in autism: a review and future directions. *Int. J. Dev. Neurosci.* 23, 183–187.

Belmonte, M., Cook, E.H., Jr., Anderson, G., Rubenstein, J., Greenough, W., Beckel-Mitchener, A., Courchesne, E., Boulanger, L., Powell, S., Levitt, P., et al. (2004). Autism as a disorder of neural information processing: directions for research and targets for therapy. *Mol. Psychiatry* 9, 646–663.

Ben Bashat, D., Kronfeld-Duenias, V., Zachor, D.A., Ekstein, P.M., Hendler, T., Tarrasch, R., Even, A., Levy, Y., and Ben Sira, L. (2007). Accelerated maturation of white matter in young children with autism: a high b value DWI study. *Neuroimage* 37, 40–47.

Bloss, C.S., and Courchesne, E. (2007). MRI neuroanatomy in young girls with autism: a preliminary study. *J. Am. Acad. Child Adolesc. Psychiatry* 46, 515–523.

Boger-Megiddo, I., Shaw, D.W., Friedman, S.D., Sparks, B.F., Artru, A.A., Giedd, J.N., Dawson, G., and Dager, S.R. (2006). Corpus callosum morphometrics in young children with autism spectrum disorder. *J. Autism. Dev. Disord.* 36, 733–739.

Buxhoeveden, D., Semendeferi, K., Buckwalter, J., Schenkar, N., Switzer, R., and Courchesne, E. (2006). Reduced minicolumns in the frontal cortex in patients with autism. *Neuropathol. Appl. Neurobiol.* 32, 483–491.

Campbell, D.B., Sutcliffe, J.S., Ebert, P.J., Militerni, R., Bravaccio, C., Trillo, S., Elia, M., Schneider, C., Melmed, R., Sacco, R., et al. (2006). A genetic variant that disrupts MET transcription is associated with autism. *Proc. Natl. Acad. Sci. USA* 103, 16834–16839.

Campbell, D., D'Oronzio, R., Garbett, K., Ebert, P., Mirnics, K., Levitt, P., and Persico, A. (2007). Disruption of cerebral cortex MET signaling in autism spectrum disorder. *Ann. Neurol.* 62, 243–250.

Carper, R.A., and Courchesne, E. (2005). Localized enlargement of the frontal cortex in early autism. *Biol. Psychiatry* 57, 126–133.

Carper, R.A., Moses, P., Tigue, Z.D., and Courchesne, E. (2002). Cerebral lobes in autism: early hyperplasia and abnormal age effects. *Neuroimage* 16, 1038–1051.

Carver, L.J., and Dawson, G. (2002). Development and neural bases of face recognition in autism. *Mol. Psychiatry* 7 (Suppl 2), S18–S20.

Casanova, M.F., Buxhoeveden, D.P., Switala, A.E., and Roy, E. (2002). Minicolumnar pathology in autism. *Neurology* 58, 428–432.

Casanova, M.F., van Kooten, I.A., Switala, A.E., van Engeland, H., Heinsen, H., Steinbusch, H.W., Hof, P.R., Trippe, J., Stone, J., and Schmitz, C. (2006). Minicolumnar abnormalities in autism. *Acta Neuropathol. (Berl)* 112, 287–303.

Castelli, F., Frith, C., Happe, F., and Frith, U. (2002). Autism, Asperger syndrome and brain mechanisms for the attribution of mental states to animated shapes. *Brain* 125, 1839–1849.

Cheour, M., Martynova, O., Naatanen, R., Erkkola, R., Sillanpaa, M., Kero, P., Raz, A., Kaipio, M.L., Hiltunen, J., Aaltonen, O., et al. (2002). Speech sounds learned by sleeping newborns. *Nature* 415, 599–600.

Cherkassky, V.L., Kana, R.K., Keller, T.A., and Just, M.A. (2006). Functional connectivity in a baseline resting-state network in autism. *Neuro-report* 17, 1687–1690.

Chubykin, A., Liu, A., Comolletti, D., Tsigelny, I., Taylor, P., and Südhof, T. (2005). Dissection of synapse induction by neuroligins: effect of a neuroligin mutation associated with autism. *J. Biol. Chem.* 280, 22365–22374.

Chung, M.K., Dalton, K.M., Alexander, A.L., and Davidson, R.J. (2004). Less white matter concentration in autism: 2D voxel-based morphometry. *Neuroimage* 23, 242–251.

- Ciesielski, K., Harris, R., Hart, B., and Pabst, H. (1997). Cerebellar hypoplasia and frontal lobe cognitive deficits in disorders of early childhood. *Neuropsychologia* 35, 643–655.
- Cody, H., Pelphrey, K., and Piven, J. (2002). Structural and functional magnetic resonance imaging of autism. *Int. J. Dev. Neurosci.* 20, 421–438.
- Conel, J.L. (1939). *The Postnatal Development of the Human Cerebral Cortex. Volume 1. The Cortex of the Newborn* (Cambridge, MA: Harvard University Press).
- Conel, J.L. (1941). *The Postnatal Development of the Human Cerebral Cortex. Volume II. The Cortex of the One-Month Infant* (Cambridge, MA: Harvard University Press).
- Conel, J.L. (1951). *The Postnatal Development of the Human Cerebral Cortex. Volume IV. The Cortex of the Six-Month Infant* (Cambridge, MA: Harvard University Press).
- Conel, J.L. (1959). *The Postnatal Development of the Human Cerebral Cortex. Volume VI. The Cortex of the Twenty-Four Month Infant* (Cambridge, MA: Harvard University Press).
- Courchesne, E., and Pierce, K. (2005a). Brain overgrowth in autism during a critical time in development: implications for frontal pyramidal neuron and interneuron development and connectivity. *Int. J. Dev. Neurosci.* 23, 153–170.
- Courchesne, E., and Pierce, K. (2005b). Why the frontal cortex in autism might be talking only to itself: local over-connectivity but long-distance disconnection. *Curr. Opin. Neurobiol.* 15, 225–230.
- Courchesne, E., Yeung-Courchesne, R., Press, G.A., Hesselink, J.R., and Jernigan, T.L. (1988). Hypoplasia of cerebellar vermal lobules VI and VII in autism. *N. Engl. J. Med.* 318, 1349–1354.
- Courchesne, E., Press, G.A., and Yeung-Courchesne, R. (1993). Parietal lobe abnormalities detected with MR in patients with infantile autism. *AJR Am. J. Roentgenol.* 160, 387–393.
- Courchesne, E., Saitoh, O., Yeung-Courchesne, R., Press, G.A., Lincoln, A.J., Haas, R.H., and Schreibman, L. (1994). Abnormality of cerebellar vermal lobules VI and VII in patients with infantile autism: identification of hypoplastic and hyperplastic subgroups with MR imaging. *AJR Am. J. Roentgenol.* 162, 123–130.
- Courchesne, E., Müller, R.-A., and Saitoh, O. (1999). Brain weight in autism: Normal in the majority of cases, megalencephalic in rare cases. *Neurology* 52, 1057–1059.
- Courchesne, E., Karns, C., Davis, H.R., Ziccardi, R., Carper, R., Tigue, Z., Pierce, K., Moses, P., Chisum, H.J., Lord, C., et al. (2001). Unusual brain growth patterns in early life in patients with autistic disorder: An MRI study. *Neurology* 57, 245–254.
- Courchesne, E., Carper, R., and Akshoomoff, N. (2003). Evidence of brain overgrowth in the first year of life in autism. *JAMA* 290, 337–344.
- Courchesne, E., Redcay, E., and Kennedy, D.P. (2004). The autistic brain: birth through adulthood. *Curr. Opin. Neurol.* 17, 489–496.
- Critchley, H.D., Daly, E.M., Bullmore, E.T., Williams, S.C.R., Van Amelsvoort, T., Robertson, D.M., Rowe, A., Phillips, M., McAlonan, G., Howlin, P., and Murphy, D.G.M. (2000). The functional neuroanatomy of social behavior: Changes in cerebral blood flow when people with autistic disorder process facial expressions. *Brain* 123, 2203–2212.
- Dalton, K.M., Nacewicz, B.M., Johnstone, T., Schaefer, H.S., Gernsbacher, M.A., Goldsmith, H.H., Alexander, A.L., and Davidson, R.J. (2005). Gaze fixation and the neural circuitry of face processing in autism. *Nat. Neurosci.* 8, 519–526.
- Dapretto, M., Davies, M.S., Pfeifer, J.H., Scott, A.A., Sigman, M., Bookheimer, S.Y., and Iacoboni, M. (2006). Understanding emotions in others: mirror neuron dysfunction in children with autism spectrum disorders. *Nat. Neurosci.* 9, 28–30.
- Dawson, G., Carver, L., Meltzoff, A.N., Panagiotides, H., McPartland, J., and Webb, S.J. (2002). Neural correlates of face and object recognition in young children with autism spectrum disorder, developmental delay, and typical development. *Child Dev.* 73, 700–717.
- Dawson, G., Webb, S.J., Carver, L., Panagiotides, H., and McPartland, J. (2004). Young children with autism show atypical brain responses to fearful versus neutral facial expressions of emotion. *Dev. Sci.* 7, 340–359.
- Dawson, G., Munson, J., Webb, S.J., Nalty, T., Abbott, R., and Toth, K. (2007). Rate of head growth decelerates and symptoms worsen in the second year of life in autism. *Biol. Psychiatry* 61, 458–464.
- Dehaene-Lambertz, G., Dehaene, S., and Hertz-Pannier, L. (2002). Functional neuroimaging of speech perception in infants. *Science* 298, 2013–2015.
- Dementieva, Y.A., Vance, D.D., Donnelly, S.L., Elston, L.A., Wolpert, C.M., Ravan, S.A., DeLong, G.R., Abramson, R.K., Wright, H.H., and Cuccaro, M.L. (2005). Accelerated head growth in early development of individuals with autism. *Pediatr. Neurol.* 32, 102–108.
- Dissanayake, C., Bui, Q.M., Huggins, R., and Loesch, D.Z. (2006). Growth in stature and head circumference in high-functioning autism and Asperger disorder during the first 3 years of life. *Dev. Psychopathol.* 18, 381–393.
- Egaas, B., Courchesne, E., and Saitoh, O. (1995). Reduced size of corpus callosum in autism. *Arch. Neurol.* 52, 794–801.
- Fombonne, E. (2005). Epidemiology of autistic disorder and other pervasive developmental disorders. *J. Clin. Psychiatry* 66 (Suppl 10), 3–8.
- Fransson, P., Skold, B., Horsch, S., Nordell, A., Blennow, M., Lagercrantz, H., and Aden, U. (2007). Resting-state networks in the infant brain. *Proc. Natl. Acad. Sci. USA* 104, 15531–15536.
- Frith, C.D., and Frith, U. (2006). The neural basis of mentalizing. *Neuron* 50, 531–534.
- Ganz, M.L. (2007). The lifetime distribution of the incremental societal costs of autism. *Arch. Pediatr. Adolesc. Med.* 161, 343–349.
- Garber, K. (2007). Autism's cause may reside in abnormalities at the synapse. *Science* 317, 190–191.
- Gillberg, C., and de Souza, L. (2002). Head circumference in autism, Asperger syndrome, and ADHD: a comparative study. *Dev. Med. Child Neurol.* 44, 296–300.
- Hadjikhani, N., Chabris, C., Joseph, R., Clark, J., McGrath, L., Aharon, I., Feczko, E., Tager-Flusberg, H., and Harris, G. (2004). Early visual cortex organization in autism: an fMRI study. *Neuroreport* 15, 267–270.
- Hadjikhani, N., Joseph, R.M., Snyder, J., and Tager-Flusberg, H. (2006). Anatomical differences in the mirror neuron system and social cognition network in autism. *Cereb. Cortex* 16, 1276–1282.
- Hadjikhani, N., Joseph, R.M., Snyder, J., and Tager-Flusberg, H. (2007). Abnormal activation of the social brain during face perception in autism. *Hum. Brain Mapp.* 28, 441–449.
- Hardan, A.Y., Minshew, N.J., and Keshavan, M.S. (2000). Corpus callosum size in autism. *Neurology* 55, 1033–1036.
- Hardan, A.Y., Kilpatrick, M., Keshavan, M.S., and Minshew, N.J. (2003). Motor performance and anatomic magnetic resonance imaging (MRI) of the basal ganglia in autism. *J. Child Neurol.* 18, 317–324.
- Hardan, A.Y., Muddasani, S., Vemulapalli, M., Keshavan, M.S., and Minshew, N.J. (2006). An MRI study of increased cortical thickness in autism. *Am. J. Psychiatry* 163, 1290–1292.
- Hazlett, H.C., Poe, M., Gerig, G., Smith, R.G., Provenzale, J., Ross, A., Gilmore, J., and Piven, J. (2005). Magnetic resonance imaging and head circumference study of brain size in autism: birth through age 2 years. *Arch. Gen. Psychiatry* 62, 1366–1376.



- Hazlett, H.C., Poe, M.D., Gerig, G., Smith, R.G., and Piven, J. (2006). Cortical gray and white brain tissue volume in adolescents and adults with autism. *Biol. Psychiatry* 59, 1–6.
- Haznedar, M.M., Buchsbaum, M.S., Wei, T.-C., Hof, P.R., Cartwright, C., Bienstock, C.A., and Hollander, E. (2000). Limbic circuitry in patients with autism spectrum disorders studied with positron emission tomography and magnetic resonance imaging. *Am. J. Psychiatry* 157, 1994–2001.
- Herbert, M.R. (2005). Large brains in autism: the challenge of pervasive abnormality. *Neuroscientist* 11, 417–440.
- Herbert, M.R., Ziegler, D.A., Deutsch, C.K., O'Brien, L.M., Lange, N., Bakardjiev, A., Hodgson, J., Adrien, K.T., Steele, S., Makris, N., et al. (2003). Dissociations of cerebral cortex, subcortical and cerebral white matter volumes in autistic boys. *Brain* 126, 1182–1192.
- Herbert, M.R., Ziegler, D.A., Makris, N., Filipek, P.A., Kemper, T.L., Normandin, J.J., Sanders, H.A., Kennedy, D.N., and Caviness, V.S., Jr. (2004). Localization of white matter volume increase in autism and developmental language disorder. *Ann. Neurol.* 55, 530–540.
- Hoshino, Y., Manome, T., Kaneko, M., Yashima, Y., and Kumashiro, H. (1984). Computed tomography of the brain in children with early infantile autism. *Folia Psychiatr. Neurol. Jpn.* 38, 33–43.
- Huttenlocher, P. (2002). *Neural Plasticity: The effects of environment on the development of cerebral cortex* (Cambridge, MA: Harvard University Press).
- Iacoboni, M., and Dapretto, M. (2006). The mirror neuron system and the consequences of its dysfunction. *Nat. Rev. Neurosci.* 7, 942–951.
- Jamain, S., Quach, H., Betancur, C., Råstam, M., Colineaux, C., Gillberg, I., Soderstrom, H., Giros, B., Leboyer, M., Gillberg, C., et al. (2003). Mutations of the X-linked genes encoding neurologins NLGN3 and NLGN4 are associated with autism. *Nat. Genet.* 34, 27–29.
- Just, M.A., Cherkassky, V.L., Keller, T.A., and Minshew, N.J. (2004). Cortical activation and synchronization during sentence comprehension in high-functioning autism: evidence of underconnectivity. *Brain* 127, 1811–1821.
- Just, M.A., Cherkassky, V.L., Keller, T.A., Kana, R.K., and Minshew, N.J. (2007). Functional and anatomical cortical underconnectivity in autism: evidence from an fMRI study of an executive function task and corpus callosum morphometry. *Cereb. Cortex* 17, 951–961.
- Kana, R.K., Keller, T.A., Cherkassky, V.L., Minshew, N.J., and Just, M.A. (2006). Sentence comprehension in autism: thinking in pictures with decreased functional connectivity. *Brain* 129, 2484–2493.
- Kates, W.R., Burnette, C.P., Eliez, S., Strunge, L.A., Kaplan, D., Landa, R., Reiss, A.L., and Pearlson, G.D. (2004). Neuroanatomic variation in monozygotic twin pairs discordant for the narrow phenotype for autism. *Am. J. Psychiatry* 161, 539–546.
- Kaufmann, W.E., Cooper, K.L., Mostofsky, S.H., Capone, G.T., Kates, W.R., Newschaffer, C.J., Bukelis, I., Stump, M.H., Jann, A.E., and Lanham, D.C. (2003). Specificity of cerebellar vermian abnormalities in autism: a quantitative magnetic resonance imaging study. *J. Child Neurol.* 18, 463–470.
- Kemper, T., and Bauman, M. (1998). Neuropathology of infantile autism. *J. Neuropathol. Exp. Neurol.* 57, 645–652.
- Kennedy, D.P., Semendeferi, K., and Courchesne, E. (2007). No reduction of spindle neuron number in frontoinsular cortex in autism. *Brain Cogn.* 64, 124–129.
- Koshino, H., Kana, R.K., Keller, T.A., Cherkassky, V.L., Minshew, N.J., and Just, M.A. (2007). fMRI investigation of working memory for faces in autism: Visual coding and underconnectivity with frontal areas. *Cereb. Cortex*, in press. Published online May 20, 2007. 10.1093/cercor/bhm054.
- Kuhl, P.K., Coffey-Corina, S., Padden, D., and Dawson, G. (2005). Links between social and linguistic processing of speech in preschool children with autism: behavioral and electrophysiological measures. *Dev. Sci.* 8, F1–F12.
- Lainhart, J.E., Piven, J., Wzorek, M., Landa, R., Santangelo, S.L., Coon, H., and Folstein, S.E. (1997). Macrocephaly in children and adults with autism. *J. Am. Acad. Child Adolesc. Psychiatry* 36, 282–290.
- Landa, R., and Garrett-Mayer, E. (2006). Development in infants with autism spectrum disorders: a prospective study. *J. Child Psychol. Psychiatry* 47, 629–638.
- Laurence, J.A., and Fatemi, S.H. (2005). Glial fibrillary acidic protein is elevated in superior frontal, parietal and cerebellar cortices of autistic subjects. *Cerebellum* 4, 206–210.
- Lee, M., Martin-Ruiz, C., Graham, A., Court, J., Jaros, E., Perry, R., Iversen, P., Bauman, M., and Perry, E. (2002). Nicotinic receptor abnormalities in the cerebellar cortex in autism. *Brain* 125, 1483–1495.
- Levitt, J., Blanton, R., Capetillo-Cunliffe, L., Guthrie, D., Toga, A., and McCracken, J. (1999). Cerebellar vermis lobules VIII-X in autism. *Prog. Neuropsychopharmacol. Biol. Psychiatry* 23, 625–633.
- Levitt, J.G., Blanton, R.E., Smalley, S., Thompson, P.M., Guthrie, D., McCracken, J.T., Sadoun, T., Heinichen, L., and Toga, A.W. (2003). Cortical sulcal maps in autism. *Cereb. Cortex* 13, 728–735.
- Lord, C., and Risi, S. (2000). Diagnosis of autism spectrum disorders in young children. In *Autism spectrum disorders: A transactional developmental perspective*, A. Wetherby and B. Prizant, eds. (Baltimore, MD: Paul H. Brookes Publishing Co.), pp. 167–190.
- Lotspeich, L.J., Kwon, H., Schumann, C.M., Fryer, S.L., Goodlin-Jones, B.L., Buonocore, M.H., Lammers, C.R., Amaral, D.G., and Reiss, A.L. (2004). Investigation of neuroanatomical differences between autism and Asperger syndrome. *Arch. Gen. Psychiatry* 61, 291–298.
- Manes, F., Piven, J., Vrancic, D., Nanclares, V., Plebst, C., and Starkstein, S.E. (1999). An MRI study of the corpus callosum and cerebellum in mentally retarded autistic individuals. *J. Neuropsychiatry Clin. Neurosci.* 11, 470–474.
- Mason, R.A., Williams, D.L., Kana, R.K., Minshew, N., and Just, M.A. (2007). Theory of Mind disruption and recruitment of the right hemisphere during narrative comprehension in autism. *Neuropsychologia*, in press. Published online August 1, 2007. 10.1016/j.neuropsychologia.2007.07.018.
- Mason-Brothers, A., Ritvo, E.R., Pingree, C., Petersen, P.B., Jenson, W.R., McMahon, W.M., Freeman, B.J., Jorde, L.B., Spencer, M.J., Mo, A., and Ritvo, A. (1990). The UCLA-University of Utah epidemiologic survey of autism: prenatal, perinatal, and postnatal factors. *Pediatrics* 86, 514–519.
- McAlonan, G.M., Cheung, V., Cheung, C., Suckling, J., Lam, G.Y., Tai, K.S., Yip, L., Murphy, D.G., and Chua, S.E. (2005). Mapping the brain in autism. A voxel-based MRI study of volumetric differences and inter-correlations in autism. *Brain* 128, 268–276.
- McPartland, J., Dawson, G., Webb, S.J., Panagiotides, H., and Carver, L.J. (2004). Event-related brain potentials reveal anomalies in temporal processing of faces in autism spectrum disorder. *J. Child Psychol. Psychiatry* 45, 1235–1245.
- Munson, J., Dawson, G., Abbott, R., Faja, S., Webb, S.J., Friedman, S.D., Shaw, D., Artru, A., and Dager, S.R. (2006). Amygdalar volume and behavioral development in autism. *Arch. Gen. Psychiatry* 63, 686–693.
- Murias, M., Webb, S.J., Greenson, J., and Dawson, G. (2007). Resting state cortical connectivity reflected in EEG coherence in individuals with autism. *Biol. Psychiatry* 62, 270–273.
- Nacewicz, B.M., Dalton, K.M., Johnstone, T., Long, M.T., McAuliff, E.M., Oakes, T.R., Alexander, A.L., and Davidson, R.J. (2006). Amygdala volume and nonverbal social impairment in adolescent and adult males with autism. *Arch. Gen. Psychiatry* 63, 1417–1428.
- Nolte, J. (1993). *The Human Brain* (St. Louis, MO: Mosby Year Book).

- Oberman, L.M., and Ramachandran, V.S. (2007). The simulating social mind: the role of the mirror neuron system and simulation in the social and communicative deficits of autism spectrum disorders. *Psychol. Bull.* 133, 310–327.
- Oberman, L.M., Hubbard, E.M., McCleery, J.P., Altschuler, E.L., Ramachandran, V.S., and Pineda, J.A. (2005). EEG evidence for mirror neuron dysfunction in autism spectrum disorders. *Brain Res. Cogn. Brain Res.* 24, 190–198.
- Palmen, S.J., van Engeland, H., Hof, P.R., and Schmitz, C. (2004). Neuropathological findings in autism. *Brain* 127, 2572–2583.
- Palmen, S.J., Hulshoff Pol, H.E., Kemner, C., Schnack, H.G., Durston, S., Lohuis, B.E., Kahn, R.S., and Van Engeland, H. (2005). Increased gray-matter volume in medication-naïve high-functioning children with autism spectrum disorder. *Psychol. Med.* 35, 561–570.
- Perrin, F., Garcia-Larrea, L., Mauguire, F., and Bastuji, H. (1999). A differential brain response to the subject's own name persists during sleep. *Clin. Neurophysiol.* 110, 2153–2164.
- Perrin, F., Bastuji, H., and Garcia-Larrea, L. (2002). Detection of verbal discordances during sleep. *Neuroreport* 13, 1345–1349.
- Pierce, K., Müller, R.-A., Ambrose, J., Allen, G., and Courchesne, E. (2001). Face processing occurs outside the fusiform 'face area' in autism: Evidence from fMRI. *Brain* 124, 2059–2073.
- Pierce, K., Haist, F., Sedaghat, F., and Courchesne, E. (2004). The brain response to personally familiar faces in autism: findings of fusiform activity and beyond. *Brain* 127, 2703–2716.
- Piven, J. (2004). Longitudinal MRI study of 18–35 month olds with autism. Paper presented at: International Meeting for Autism Research (Sacramento, CA).
- Piven, J., Nehme, E., Simon, J., Barta, P., Pearlson, G., and Folstein, S.E. (1992). Magnetic resonance imaging in autism: measurement of the cerebellum, pons, and fourth ventricle. *Biol. Psychiatry* 31, 491–504.
- Piven, J., Arndt, S., Bailey, J., Haverkamp, S., Andreasen, N.C., and Palmer, P. (1995). An MRI study of brain size in autism. *Am. J. Psychiatry* 152, 1145–1149.
- Piven, J., Bailey, J., Ranson, B.J., and Arndt, S. (1997). An MRI study of the corpus callosum in autism. *Am. J. Psychiatry* 154, 1051–1055.
- Redcay, E., and Courchesne, E. (2005). When is the brain enlarged in autism? A meta-analysis of all brain size reports. *Biol. Psychiatry* 58, 1–9.
- Redcay, E., Haist, F., and Courchesne, E. (2007a). Functional neuroimaging of speech perception during a pivotal period in language acquisition. *Dev. Sci.*, in press.
- Redcay, E., Kennedy, D.P., and Courchesne, E. (2007b). fMRI during natural sleep as a method to study brain function during early childhood. *Neuroimage*, in press. Published online August 17, 2007. 10.1016/j.neuroimage.2007.08.005.
- Rice, S.A., Bigler, E.D., Cleavinger, H.B., Tate, D.F., Sayer, J., McMahon, W., Ozonoff, S., Lu, J., and Lainhart, J.E. (2005). Macrocephaly, corpus callosum morphology, and autism. *J. Child Neurol.* 20, 34–41.
- Rippon, G., Brock, J., Brown, C., and Boucher, J. (2007). Disordered connectivity in the autistic brain: challenges for the "new psychophysiology". *Int. J. Psychophysiol.* 63, 164–172.
- Rogers, S.J., and Di Lalla, D. (1990). Age of symptom onset in young children with pervasive developmental disorders. *J. Am. Acad. Child Adolesc. Psychiatry* 29, 863–872.
- Rojas, D.C., Bawn, S.D., Benkers, T.L., Reite, M.L., and Rogers, S.J. (2002). Smaller left hemisphere planum temporale in adults with autistic disorder. *Neurosci. Lett.* 328, 237–240.
- Rojas, D.C., Camou, S.L., Reite, M.L., and Rogers, S.J. (2005). Planum temporale volume in children and adolescents with autism. *J. Autism Dev. Disord.* 35, 479–486.
- Rubenstein, J.L., and Merzenich, M.M. (2003). Model of autism: increased ratio of excitation/inhibition in key neural systems. *Genes Brain Behav.* 2, 255–267.
- Schmitz, N., Daly, E., and Murphy, D. (2007). Frontal anatomy and reaction time in autism. *Neurosci. Lett.* 412, 12–17.
- Schultz, R.T., Gauthier, I., Klin, A., Fulbright, R.K., Anderson, A.W., Volkmar, F., Skudlarski, P., Lacadie, C., Cohen, D.J., and Gore, J.C. (2000). Abnormal ventral temporal cortical activity during face discrimination among individuals with autism and Asperger syndrome. *Arch. Gen. Psychiatry* 57, 331–340.
- Schultz, R., Win, L., Jackowski, A., Klin, A., Staib, L., Papademetris, X., Babitz, T., Carter, E., Klaiman, C., Fieler, A., et al. (2005). Brain Morphology in Autism Spectrum Disorders. Paper presented at: The International Meeting for Autism Research (Boston, MA).
- Schumann, C.M., and Amaral, D.G. (2006). Stereological analysis of amygdala neuron number in autism. *J. Neurosci.* 26, 7674–7679.
- Schumann, C.M., Hamstra, J., Goodlin-Jones, B.L., Lotspeich, L.J., Kwon, H., Buonocore, M.H., Lammers, C.R., Reiss, A.L., and Amaral, D.G. (2004). The amygdala is enlarged in children but not adolescents with autism; the hippocampus is enlarged at all ages. *J. Neurosci.* 24, 6392–6401.
- Sebat, J., Lakshmi, B., Malhotra, D., Troge, J., Lese-Martin, C., Walsh, T., Yamrom, B., Yoon, S., Krasnitz, A., Kendall, J., et al. (2007). Strong association of de novo copy number mutations with autism. *Science* 316, 445–449.
- Sparks, B.F., Friedman, S.D., Shaw, D.W., Aylward, E., Echelard, D., Artru, A.A., Maravilla, K.R., Giedd, J.N., Munson, J., Dawson, G., and Dager, S.R. (2002). Brain structural abnormalities in young children with autism spectrum disorder. *Neurology* 59, 184–192.
- Stevenson, R.E., Schroer, R.J., Skinner, C., Fender, D., and Simensen, R.J. (1997). Autism and macrocephaly. *Lancet* 349, 1744–1745.
- Tsatsanis, K.D., Rourke, B.P., Klin, A., Volkmar, F.R., Cicchetti, D., and Schultz, R.T. (2003). Reduced thalamic volume in high-functioning individuals with autism. *Biol. Psychiatry* 53, 121–129.
- Vargas, D.L., Nascimbene, C., Krishnan, C., Zimmerman, A.W., and Pardo, C.A. (2005). Neuroglial activation and neuroinflammation in the brain of patients with autism. *Ann. Neurol.* 57, 67–81.
- Vidal, C.N., Nicolson, R., Devito, T.J., Hayashi, K.M., Geaga, J.A., Drost, D.J., Williamson, P.C., Rajakumar, N., Sui, Y., Dutton, R.A., et al. (2006). Mapping corpus callosum deficits in autism: an index of aberrant cortical connectivity. *Biol. Psychiatry* 60, 218–225.
- Villalobos, M.E., Mizuno, A., Dahl, B.C., Kemmotsu, N., and Muller, R.-A. (2005). Reduced functional connectivity between V1 and inferior frontal cortex associated with visuomotor performance in autism. *Neuroimage* 25, 916–925.
- Wang, A.T., Dapretto, M., Hariri, A.R., Sigman, M., and Bookheimer, S.Y. (2004). Neural correlates of facial affect processing in children and adolescents with autism spectrum disorder. *J. Am. Acad. Child Adolesc. Psychiatry* 43, 481–490.
- Wang, A.T., Lee, S.S., Sigman, M., and Dapretto, M. (2007). Reading affect in the face and voice: neural correlates of interpreting communicative intent in children and adolescents with autism spectrum disorders. *Arch. Gen. Psychiatry* 64, 698–708.
- Wetherby, A.M., Woods, J., Allen, L., Cleary, J., Dickinson, H., and Lord, C. (2004). Early indicators of autism spectrum disorders in the second year of life. *J. Autism Dev. Disord.* 34, 473–493.
- Wilke, M., Holland, S.K., and Ball, W.S., Jr. (2003). Language processing during natural sleep in a 6-year-old boy, as assessed with functional MR imaging. *AJNR Am. J. Neuroradiol.* 24, 42–44.

Williams, J.H., Whiten, A., Suddendorf, T., and Perrett, D.I. (2001). Imitation, mirror neurons and autism. *Neurosci. Biobehav. Rev.* 25, 287–295.

Williams, J.H., Waite, G.D., Gilchrist, A., Perrett, D.I., Murray, A.D., and Whiten, A. (2006). Neural mechanisms of imitation and 'mirror neuron' functioning in autistic spectrum disorder. *Neuropsychologia* 44, 610–621.

Zhao, X., Leotta, A., Kustanovich, V., Lajonchere, C., Geschwind, D.H., Law, K., Law, P., Qiu, S., Lord, C., Sebat, J., et al. (2007). A unified genetic theory for sporadic and inherited autism. *Proc. Natl. Acad. Sci. USA* 104, 12831–12836.

Zwaigenbaum, L., Bryson, S., Rogers, T., Roberts, W., Brian, J., and Szatmari, P. (2005). Behavioral manifestations of autism in the first year of life. *Int. J. Dev. Neurosci.* 23, 143–152.