

Neuroanatomy of autism

David G. Amaral¹, Cynthia Mills Schumann² and Christine Wu Nordahl¹

¹The M.I.N.D. Institute, Department of Psychiatry and Behavioral Sciences, University of California, Davis, 2825 50th Street, Sacramento, CA 95817, USA

²Department of Neurosciences, University of California, San Diego, 8110 La Jolla Shores Drive, Suite 201, La Jolla, CA 92037, USA

Autism spectrum disorder is a heterogeneous, behaviorally defined, neurodevelopmental disorder that occurs in 1 in 150 children. Individuals with autism have deficits in social interaction and verbal and nonverbal communication and have restricted or stereotyped patterns of behavior. They might also have co-morbid disorders including intellectual impairment, seizures and anxiety. Postmortem and structural magnetic resonance imaging studies have highlighted the frontal lobes, amygdala and cerebellum as pathological in autism. However, there is no clear and consistent pathology that has emerged for autism. Moreover, recent studies emphasize that the time course of brain development rather than the final product is most disturbed in autism. We suggest that the heterogeneity of both the core and co-morbid features predicts a heterogeneous pattern of neuropathology in autism. Defined phenotypes in larger samples of children and well-characterized brain tissue will be necessary for clarification of the neuroanatomy of autism.

Introduction

Autism is a heterogeneous disorder with multiple causes and courses, a great range in the severity of symptoms, and several associated co-morbid disorders. Increasingly, researchers refer to ‘the autisms’ rather than a single autism phenotype [1]. It would be surprising, therefore, if the neuropathology of autism was identical across all affected individuals.

The core and co-morbid features of autism

As initially described by Kanner [2], individuals with autism have three core features: (i) impairments in reciprocal social interactions; (ii) an abnormal development and use of language; and (iii) repetitive and ritualized behaviors and a narrow range of interests. In addition to the core features of autism, there are common co-morbid neurological disorders [3]. The prevalence of mental retardation in idiopathic autism is ~60% although, when the autism spectrum is taken as a whole, the number is closer to 30% [4]. Epilepsy has long been associated with autism although estimates of the occurrence of seizure disorder vary from 5% to 44% [5]. Anxiety and mood disorders are also very common in autism [6].

There is also substantial heterogeneity in the onset of autism. Some children have signs of developmental delays within the first 18 months of life. However, 25%–40% of children with autism initially demonstrate near-normal development until 18–24 months, when they regress into

an autism that is generally indistinguishable from early-onset autism [7]. The possibility that there is early-onset versus regressive phenotypes of autism might have important implications for the types and time courses of neuropathology that one might expect to encounter.

Where might one expect to see neuropathology?

In Figure 1, we summarize the major brain regions that form the putative neural systems involved in the functions that are most impacted by the core features of autism. Several brain regions have been implicated in social behavior through experimental animal studies, lesion studies in human patients or functional imaging studies [8]. These include regions of the frontal lobe, the superior temporal cortex, the parietal cortex and the amygdala. Language function is distributed throughout several cortical and subcortical regions. Foremost for expressive language function is Broca’s area in the inferior frontal gyrus and portions of the supplementary motor cortex. Wernicke’s area is essential for receptive language function, and the superior temporal sulcus plays a role in both language processing and social attention [9]. Finally, the repetitive or stereotyped behaviors of autism share many similarities with the abnormal actions of obsessive-compulsive disorder that implicate regions such as the orbitofrontal cortex and caudate nucleus [10,11].

The co-morbid disorders of autism are a matter of concern for the interpretation of the neuroanatomy of autism. Epilepsy, for example, is associated with pathology of the cerebral cortex, amygdala, cerebellum and hippocampal formation, all of which have also been implicated in autism. Unfortunately, the majority of cases evaluated in earlier postmortem studies [12,13] involved autistic brains from individuals who had co-morbid seizure disorders.

Neuroanatomy of autism

Experimental techniques

Structural magnetic resonance imaging (MRI) is a safe, relatively noninvasive tool for evaluating gross neuroanatomical changes related to autism. An ideal study would include a very large sample size (i.e. hundreds of subjects) of well-characterized individuals of both genders [14], imaged at birth and followed longitudinally at least into late childhood or early adolescence. The ideal study, however, has not been carried out. Many have been hampered by small sample sizes and virtually all are limited to cross-sectional design (see Ref. [15] for a review). Furthermore, the majority of imaging studies examine populations of older and higher-functioning individuals. Because the diagnosis of autism cannot reliably be made until around

Corresponding author: Amaral, D.G. (dgamaral@ucdavis.edu).

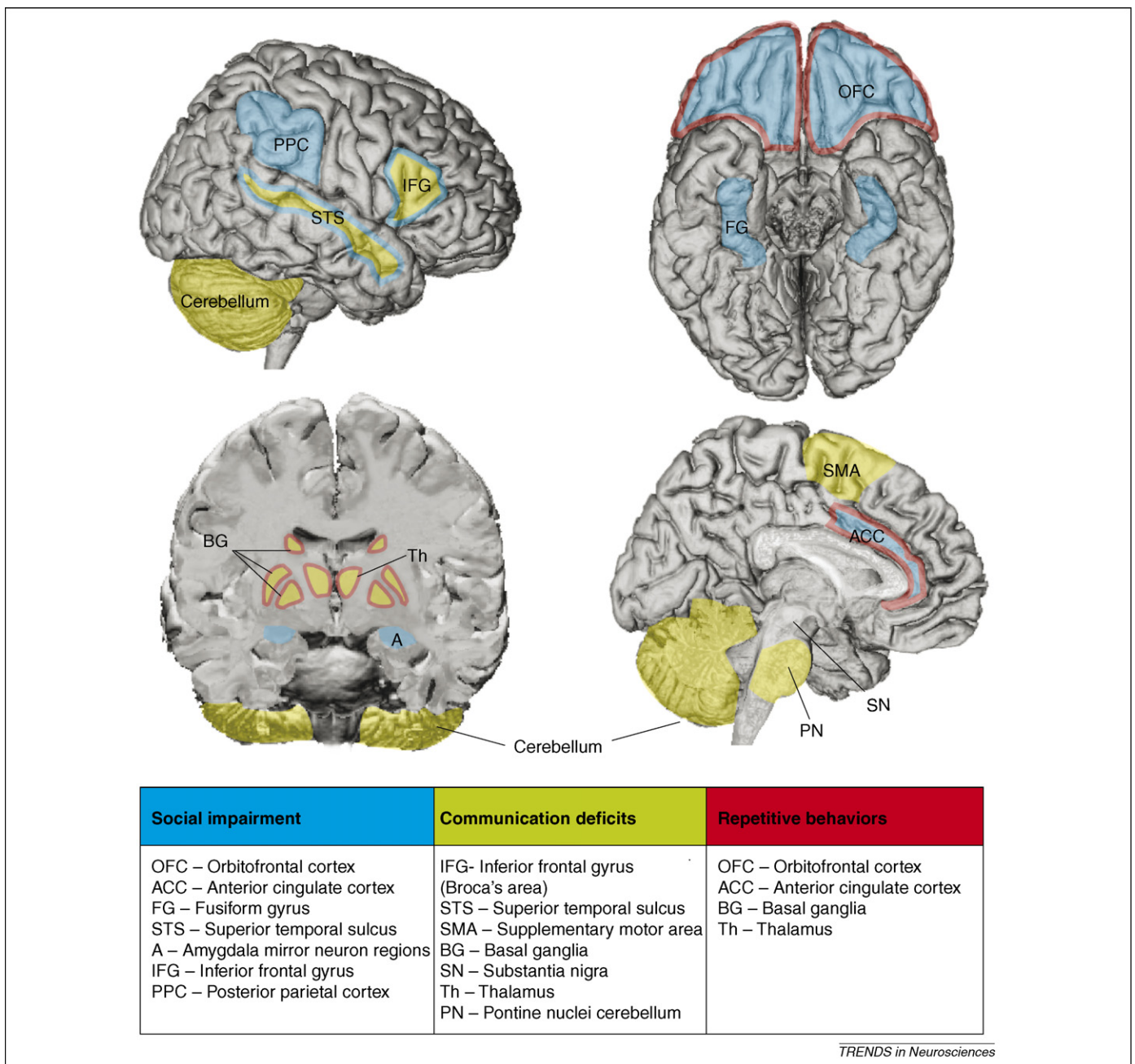


Figure 1. Brain areas that have been implicated in the mediation of the three core behaviors that are impaired in autism: social behavior, language and communication, and repetitive and stereotyped behaviors.

2–3 years of age, the current field of MRI studies might be defining the end result of the pathology of autism rather than the etiological changes taking place during onset.

Whereas MRI provides a reliable method for studying gross neuropathology in a large number of subjects over time, postmortem techniques provide a tool for understanding the underlying neurobiology of observed neuroanatomical abnormalities (e.g. if the brain is larger, are there more neurons, fibers, axons, glia or synapses?). For these studies, controlling for confounding factors by excluding or segregating co-morbid conditions is essential. The use of postmortem techniques as a tool for studying the neuroanatomy of autism is still very much in its infancy, with fewer than 100 autism cases studied to date and a mean sample size of 5 autism cases per study.

Differences in total brain volume

Currently, one of the most prominent theories of the neuropathology of autism is that the brain undergoes a period of precocious growth during early postnatal life followed by a deceleration in age-related growth [16]. The evidence for this early overgrowth comes from four studies of head circumference, a proxy for brain size, that provide evidence for normal or smaller head circumference at birth followed by an increase in the rate of growth beginning at ~12 months of age [16–19]. Existing MRI studies suggest that very young children with autism (ages 18 months to 4 years) have a 5%–10% abnormal enlargement in total brain volume [19–21], but whether this enlargement persists into later childhood and adolescence is not as clear [20,22–26] (Figure 2).

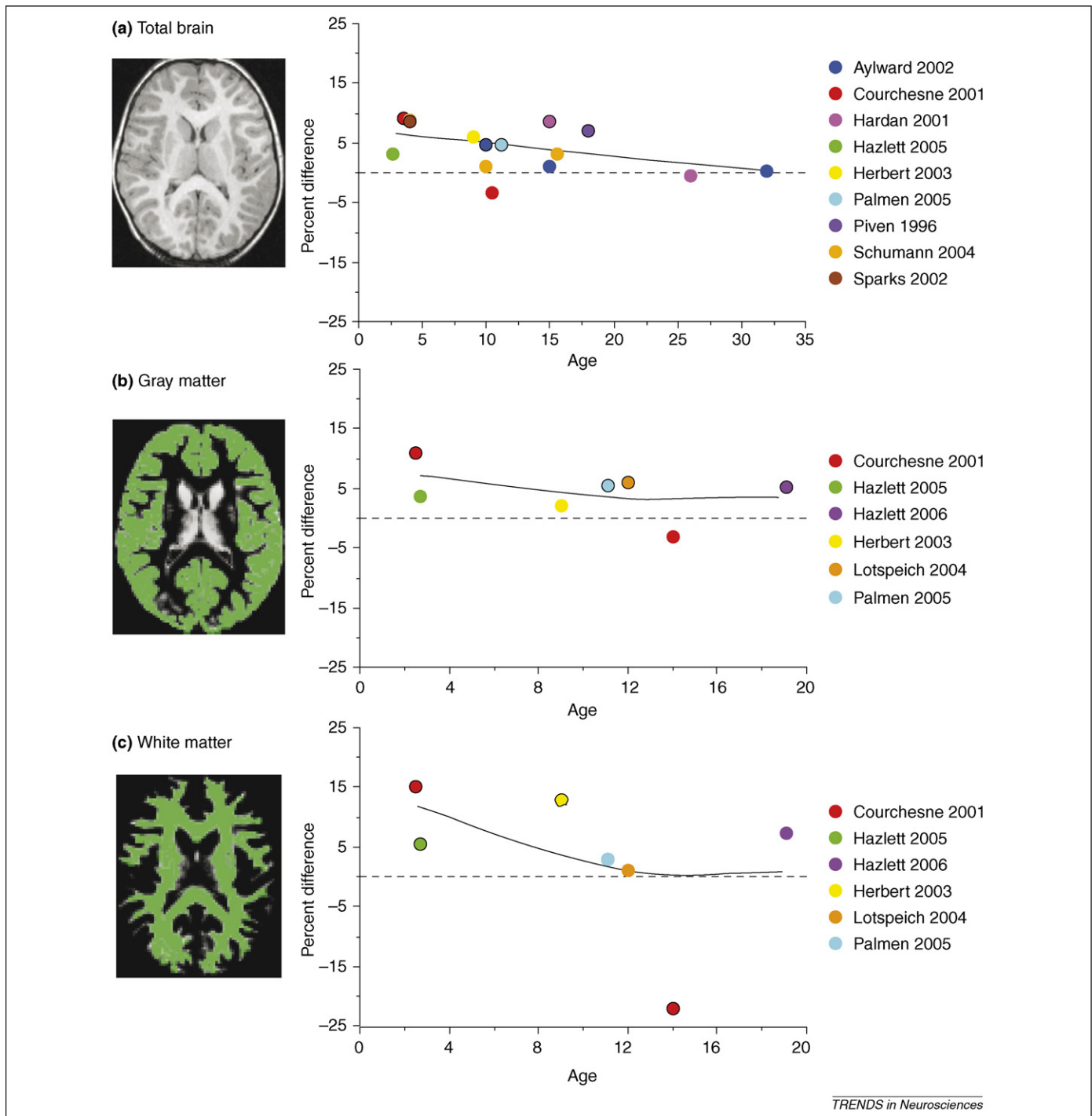


Figure 2. Percent difference between autism or autism spectrum groups and typical development with best-fit curves for (a) total brain volume, (b) gray matter and (c) white matter, based on existing MRI literature. Only studies with direct statistical comparisons between control and autism cases are included. Differences that are statistically significant ($p < .05$) are depicted with a black outline around the colored circle. Earlier studies with samples that were later included in larger studies are not included. For comparison purposes, when possible, only data from males are represented. With the exception of Sparks 2002 [21] and Schumann 2004 [25], total brain volume measures include brainstem and cerebellum. For Hazlett 2005 [19], percent difference between autism and typically developing controls (not developmentally delayed controls) is represented. For Schumann 2004 [25], percent difference between high-functioning autism (not low-functioning or Asperger's syndrome) and typically developing controls is represented. For Hazlett 2005 [19], the total gray matter difference is significant for left hemisphere only. For Hazlett 2006 [28], cerebral white matter, not total white matter, is significantly larger than typically developing controls. Aylward 2002 [22]; Courchesne 2001 [20]; Hardan 2001 [46]; Hazlett 2005 [19]; Hazlett 2006 [28]; Herbert 2003 [23]; Lotspeich 2004 [27]; Palmen 2005 [24]; Piven 1996 [26]; Schumann 2004 [25]; Sparks 2002 [21].

Collectively, head circumference and MRI studies of total brain volume indicate a putative period of abnormal brain growth beginning in the first year of life that results in a persistent enlargement at least through early childhood. It is important to emphasize that brain enlargement

observed in cross-sectional studies does not necessarily imply accelerated growth. The observation of presumed precocious brain growth awaits confirmation by a longitudinal MRI study. Furthermore, if the rate of brain growth is indeed accelerated, additional studies will be

needed to address whether there is an increased rate of normal neurodevelopmental processes or entirely abnormal processes unique to the disorder.

Do increases in brain size equally involve gray and white matter?

Another prominent theory, postulated by Herbert *et al.* [23], is that the abnormal brain enlargement observed in children with autism is disproportionately accounted for by increased white matter, not gray matter. Indeed, two studies of very young children (1.5–4 years) [19,20] show greater increases in white matter than gray matter (Figure 2b,c). But again, whether these increases persist into later childhood and adolescence is less clear [24,27,28].

Existing evidence on gray matter volume suggests that although gray matter enlargement might be proportionately smaller than white matter enlargement early in life, the enlargement might persist into adulthood (Figure 2b). Four studies, collectively spanning early childhood through adolescence and adulthood, report 6%–12% enlargement of gray matter [20,24,27,28]. Additional imaging techniques, such as spectroscopy and T2 relaxometry, that can examine microstructural aspects of gray and white matter, will be important to further explore underlying etiologies of gray and white matter abnormalities.

One MRI technique that holds great promise in investigating white matter integrity is diffusion tensor imaging (DTI). Fractional anisotropy (FA) is a measure that reflects the degree of isotropic movement of water in a given voxel; higher FA values reflect denser or more ordered brain structure. Two studies in older children and adults show reductions in FA in cerebral white matter [29,30], with consistent reductions reported in and near the genu of the corpus callosum. A recent DTI and volumetric study of the corpus callosum found a 14% reduction in corpus callosum size was associated with reduced FA in the genu and splenium [31]. However, the one DTI study of toddlers [32] with autism reported differences in FA and other diffusion-weighted variables, indicating an increase in white matter maturity.

Is there any regional specificity to gray and white matter differences?

Although enlargements in gray and white matter have been reported in frontal, temporal, and parietal lobes, the largest and most consistent increases have been reported in the frontal lobes [24,28,33,34]. Within the frontal lobes, no consistent pattern of regional specificity has emerged. There is some evidence for greater increases in dorsolateral prefrontal and medial frontal cortex [34,35] but less consistent findings of no difference or decreases in orbitofrontal cortex [36,37]. Some of these inconsistencies might be a result of differences in the definition and delineation of these frontal cortical regions. A perusal of this literature emphasizes the need for the field of developmental neuropathology to establish a systematic approach to evaluating abnormal brain development.

Several MRI studies have examined other aspects of the cerebral cortex, such as sulcal patterns, cortical shape and cortical thickness. Abnormalities in cortical shape have been identified in the sylvian fissure, superior temporal

sulcus, intraparietal sulcus and inferior frontal gyrus [38,39]. Of the two studies on cortical thickness, one reported increased cortical thickness over the entire cerebral cortex, primarily driven by increases in parietal and temporal cortices [40] in 8- to 12-year-olds, whereas the other study reported cortical thinning in frontal, parietal and temporal regions in adults [41].

Postmortem cortical neuropathology

As discussed above, MRI studies have consistently found increases in brain size in younger children with autism followed by an abnormal growth pattern through adolescence. What does this tell us about the neuropathology of autism? If the brain is larger, are there too many neurons, glia, synapses and so forth? If the difference in brain size does not persist into adulthood, what neuropathological underpinnings account for this phenomenon of an abnormal growth trajectory? With the availability of more abundant, high-quality postmortem tissue and employing modern neuroanatomical techniques such as stereological methods for counting neurons and *in situ* hybridization for evaluating expression levels of genes, answering these questions might be possible in the future.

To date, only a few postmortem studies have been published on the cortical neuropathology of autism, and quantitative studies are sparser yet. Besides early case studies, Kemper and Bauman [13] were the first to carry out a qualitative neuropathological investigation in a study that included six cases of autism (5/6 with mental retardation, 4/6 with seizures). The only area of consistent abnormality in the cerebral cortex they identified was the anterior cingulate cortex that appeared unusually coarse and poorly laminated. Bailey *et al.* [12] qualitatively examined six cases of autism with mental retardation, four of which had seizures, compared to seven controls. Cortical dysgenesis was observed in four of the six autism cases, including increased cortical thickness, high neuronal density, neurons present in the molecular layer, and irregular laminar patterns. Ectopic gray matter and an increased number of neurons in the white matter were observed in three of the autism cases.

Alterations of the columnar structure of the neocortex: the minicolumn hypothesis

Increasing interest has been placed on the notion, advanced by Casanova and colleagues [42–44], that there are an abnormal number and width of minicolumns (Box 1) in individuals with autism. Only 14 cases of autism (9 of which had seizures and at least 10 with mental retardation) have been examined for minicolumnar pathology in cortical layer III in three independent studies using varying techniques [42–44]. The most consistent finding in these studies is reduced intercolumnar width of the minicolumns (only layer III has been studied thus far) in dorsolateral prefrontal cortex or Brodmann's area (BA) 9. These findings, coupled with increases in neuronal density on the order of 23% noted by Casanova *et al.* [44], imply that there should be a greater number of neurons in BA 9 of the autistic cortex. Given the narrower neuropil area between columns, one would also predict a decrease in the dendritic arborization of BA 9 neurons.

Box 1. Brain development and minicolumns

For over a century, neuroanatomists have remarked on the columnar structure of the neocortex [70]. The smallest column has come to be called the ‘minicolumn’ or ‘microcolumn’ [71,72]. The minicolumn can be identified by the stacking of neuronal cell bodies, particularly in layers III and V of the neocortex (Figure 1e, adapted from [73]). Mountcastle proposed that minicolumns are the basic functional unit of the brain [74], although the significance of the vertical organization of neurons has been a topic of much debate [71].

Minicolumn formation has been associated with early stages of cortical development when postmitotic neurons ascend in linear arrays along a radial glial scaffolding [75]. Figure 1a–c depicts cell body-stained sections of BA 9 at 1, 6 and 24 months of age [76]. Below

each is a representative Golgi-stained section showing the extent of dendritic growth in this same cortical area over these same ages. Within the first year of life, there is a dramatic increase in dendritic growth. By 2 years of age, the minicolumns are spaced farther apart with a lower cell density in a given region of cortex. Dendritic bundles and axonal fascicles that extend throughout several layers of the cortex occupy the space between minicolumns [70–72].

Casanova and colleagues [42–44] have posed the reasonable question of whether there is perturbation in the fundamental organization of minicolumns in the autistic brain. Preliminary data described in the text indicate aberrant columnar structure in layer III with less space between cell body-defined minicolumns (Figure 1d).

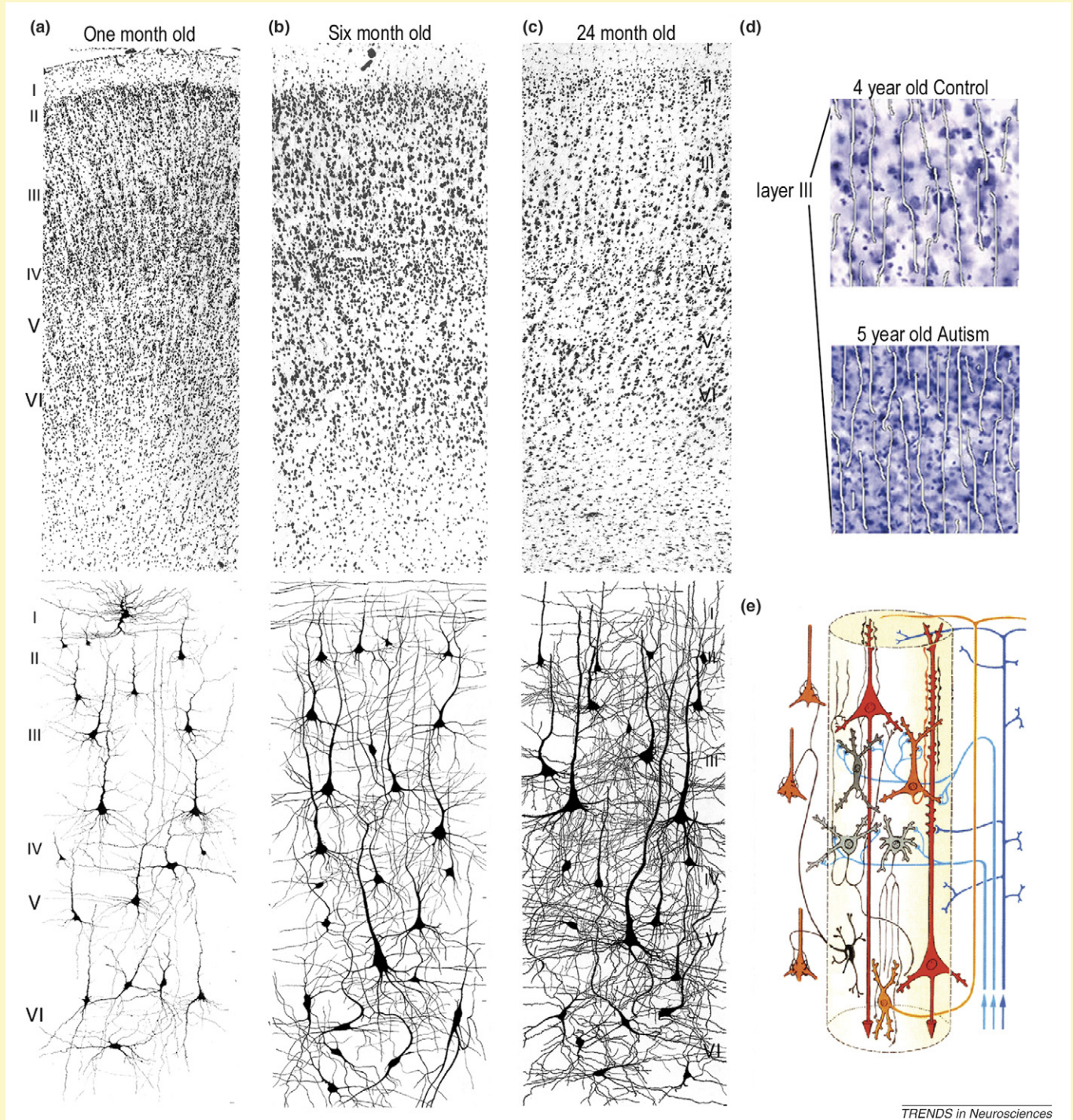


Figure 1. Features of neocortical organization potentially altered in autism.

These neuropathological questions are ripe for analysis using systematic stereological methods.

Neuropathology of the cerebellum

Five MRI studies of individuals with autism at a wide range of ages have found the cerebellum to be enlarged relative to controls [45]. However, this increase in cerebellar volume is generally proportional to total brain volume, with one exception in which the difference exceeded that of the cerebrum [46]. Only one published study to date has examined children younger than age 3, and this study did not find a difference in cerebellar size between the children at risk for autism and typically developing controls [19].

In contrast to the total cerebellum, the size of the vermis appears to be slightly smaller in some individuals with autism [47,48]. All but one study on the size of the vermis report areal measurements from a single, midsagittal section per subject, a measure that can be difficult to make reliably. Results from the same laboratory indicate that the autistic vermis can either be smaller or larger than controls [48], and size differences are likely because of the heterogeneity in the autism phenotype [49]. In addition, cerebellar vermal hypoplasia is not specific to autism, but commonly found in various developmental and psychiatric disorders and/or mental retardation [47,50].

The cerebellum has also been of substantial interest in postmortem studies of autism. Of the 24 postmortem cases of autism reported in the literature in which the cerebellum was studied, 19 (or 79%) show decreased density of Purkinje cells, particularly in the hemispheres [12,13,51,52]. Interestingly, a recent study found 40% less

expression of GAD67 mRNA in the cerebellar Purkinje cells of individuals with autism [53]. Whether the observations of lower Purkinje cell number and density actually reflect fewer Purkinje cells in the autistic brain awaits confirmation with stereological neuron counting methods.

Although the postmortem finding of fewer Purkinje cells appears to stand in stark contrast to the MRI finding of an enlarged cerebellum in autism, several factors make the two findings impossible to compare. Twenty-two of the 24 brains examined in postmortem studies came from individuals who also had mental retardation [12,13,51,52]. Almost half of the brains were from individuals with epilepsy and some individuals who were taking anticonvulsive medications that might themselves damage Purkinje cells. By contrast, most of the MRI studies were conducted with high-functioning individuals with autism and typically excluded subjects with seizure disorders from the study. So, two very different cohorts of subjects are being studied with these different techniques.

Neuropathology of the amygdala

The amygdala (Figure 3) in boys with autism appears to undergo an abnormal developmental time course that includes a period of precocious enlargement that persists through late childhood [21,25]. Sparks *et al.* [21] found a 13%–16% abnormal enlargement of the amygdala in young children with autism (36–56 months of age). Recent studies suggest that amygdala enlargement is associated with more severe anxiety [54] and worse social and communication skills [55].

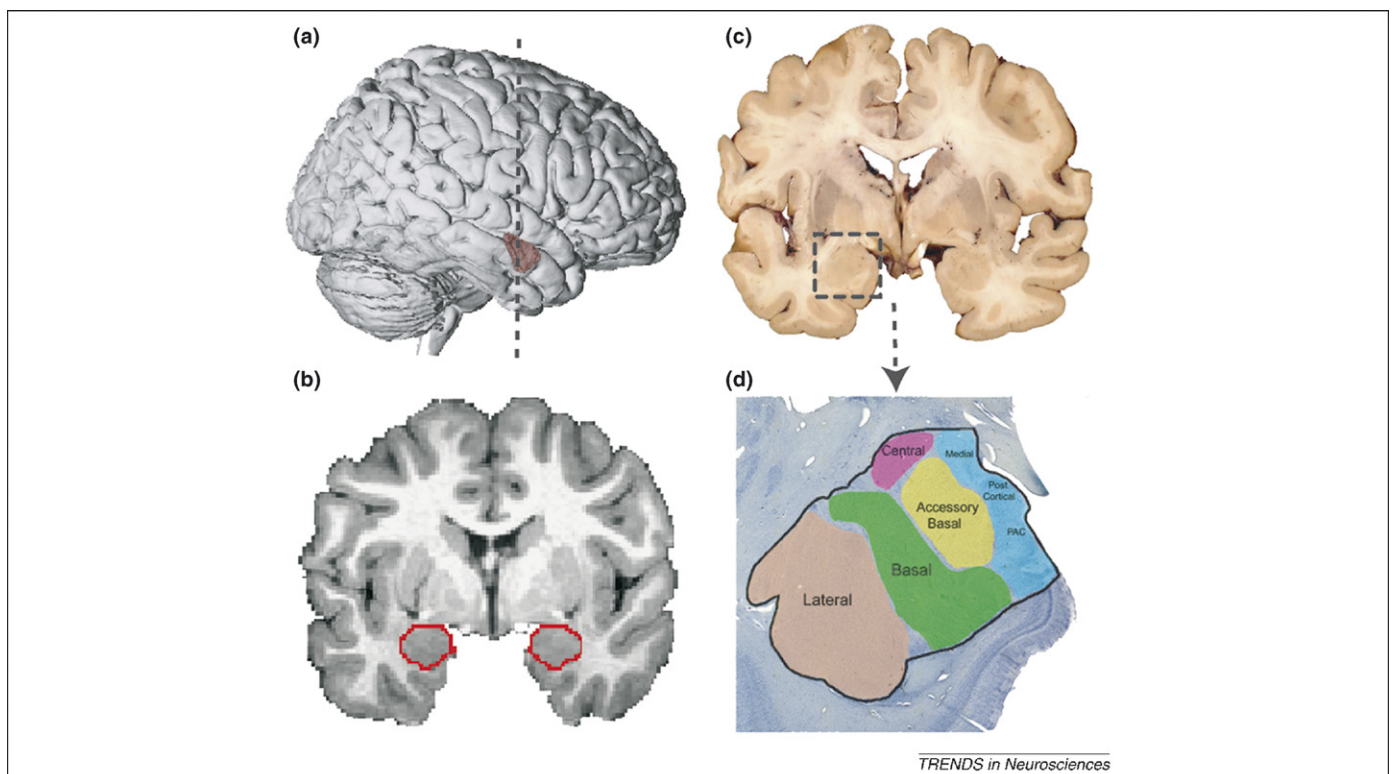


Figure 3. Neuroanatomy of the human amygdala. (a) Lateral view of a three-dimensional reconstruction of an MRI (dashed line represents location of coronal slice in (b)), (b) MRI coronal image with amygdala outlined (red), (c) coronal section of brain tissue (box around amygdala) and (d) Nissl-stained section of amygdala nuclei. PAC = peri-amygdaloid cortex.

Schumann *et al.* [25] examined the amygdala in 8- to 18-year-old boys and also found evidence of an altered developmental time course. The amygdala was enlarged by 15% in 8- to 12-year-old boys with autism relative to typically developing controls, but did not differ in 13- to 18-year-old boys. Whereas the amygdala in typically developing boys increased in size by ~40% from 8 to 18 years of age, the same growth trajectory did not occur in the boys with autism. Although these findings await confirmation from a longitudinal study, the amygdala appears initially to be larger than normal in children with autism, but does not undergo the same preadolescent age-related increase in volume that takes place in typically developing boys. Studies focused primarily on older adolescents, adults or a wide age range of subjects have found no difference [56] or even smaller [57–59] amygdala volumes in individuals with autism relative to age-matched controls.

Kemper and Bauman [13] were the first to report abnormalities in the microscopic organization of the amygdala. Qualitative observations in six postmortem cases of autism ages 9–29 years (5/6 with mental retardation, 4/6 with seizure disorder) indicated that neurons in certain nuclei of the amygdala of autism cases appeared unusually small and more densely packed than in age-matched controls. Schumann and Amaral [60] carried out a design-based stereological study to estimate the number and size of neurons in the amygdala (Figure 3) in nine autism cases 10–44 years of age without seizure disorder compared to ten typically developing age-matched male controls. The autism group had significantly fewer neurons in the total amygdala and in the lateral nucleus than the controls. They did not find increased neuronal density or decreased size of neurons as Kemper and Bauman [13] had reported.

If the decreased number of neurons in the amygdala is found to be a reliable characteristic of autism, what might account for this finding? Two possible hypotheses are: (i) fewer neurons were generated during early development, or (ii) a normal or even excessive number of neurons was generated initially, which would be consistent with MRI findings of a larger amygdala in early childhood, but some of these have subsequently been eliminated during adulthood. Unfortunately, there is currently no evidence to support or reject either of these possibilities.

Other brain regions

The investigation of other brain regions that might be affected in autism (Figure 1) is limited. There is little MRI evidence and no postmortem evidence for abnormalities in the thalamus [61–63] and basal ganglia [64–67]. There is evidence for enlargement of the caudate nucleus that might be correlated with the presence of repetitive and ritualistic behaviors in adolescents and young adults [64,65]. There is also evidence, although somewhat inconsistent (see Ref. [45] for a review), for abnormalities within the hippocampus, both in volume [25] and more recently in shape [68,69]. In postmortem studies, Kemper and Bauman [13] reported increased cell packing density and smaller neurons in the hippocampus in all autism cases examined. However, this finding was not replicated by Bailey *et al.* [12], who reported increased cell packing density in only one of the five cases examined.

Where do we go from here?

Given the enormous heterogeneity in the manifestation of core features of autism spectrum disorders, varied occurrence of significant co-morbid syndromes and generally small sample sizes of both MRI and postmortem studies of autism, it is remarkable that any significant group differences have been detected. It would not be surprising, therefore, if more clear-cut pathology emerges once distinct phenotypes of the disorder are considered as factors in the analyses.

Attempts at defining the neuroanatomy of autism are obviously in their infancy. The field will benefit both from the application of classical techniques such as the Golgi method as well as modern molecular neuroanatomical procedures such as *in situ* hybridization and single-cell PCR. It is imperative that more systematic and quantitative studies become the norm rather than the exception. All of these studies will rely, however, on the acquisition and sharing of higher-quality and a higher number of post-mortem brain specimens. In this regard, consolidated national efforts such as the Autism Tissue Program should be supported.

It is also important that noninvasive imaging techniques be applied to larger populations of better-phenotyped individuals. Imaging studies that start at the earliest possible age and are longitudinal rather than cross-sectional should be encouraged. Because autism is likely to involve both abnormal brain structure and connections, techniques that noninvasively probe brain connectivity and function should also be promoted. One has the sense that the real secrets of the neuropathology of autism have yet to be uncovered. This makes the search even more critical and exciting.

Acknowledgements

The authors have been supported by NIH grants R37 MH057502 and MH41479. C.W.N. was a Fellow of the Autism Research Training Program (T32 MH07134). We would like to thank the following colleagues who read earlier versions of this manuscript and provided helpful advice: Margaret Bauman, Gene Blatt, Manuel Casanova, Joseph Piven, Sally Ozonoff and two anonymous reviewers.

References

- 1 Geschwind, D.H. and Levitt, P. (2007) Autism spectrum disorders: developmental disconnection syndromes. *Curr. Opin. Neurobiol.* 17, 103–111
- 2 Kanner, L. (1943) Autistic disturbances of affective contact. *Nervous Child* 2, 217–250
- 3 DiCicco-Bloom, E. *et al.* (2006) The developmental neurobiology of autism spectrum disorder. *J. Neurosci.* 26, 6897–6906
- 4 Fombonne, E. (2006) Past and future perspectives on autism epidemiology. In *Understanding Autism from Basic Neuroscience to Treatment* (Moldin, S.O. and Rubenstein, J.L.R., eds), pp. 25–48, Taylor and Francis
- 5 Tuchman, R. and Rapin, I. (2002) Epilepsy in autism. *Lancet Neurol.* 1, 352–358
- 6 Lecavalier, L. (2006) Behavioral and emotional problems in young people with pervasive developmental disorders: relative prevalence, effects of subject characteristics, and empirical classification. *J. Autism Dev. Disord.* 36, 1101–1114
- 7 Werner, E. and Dawson, G. (2005) Validation of the phenomenon of autistic regression using home videotapes. *Arch. Gen. Psychiatry* 62, 889–895
- 8 Adolphs, R. (2001) The neurobiology of social cognition. *Curr. Opin. Neurobiol.* 11, 231–239

- 9 Redcay, E. (2008) The superior temporal sulcus performs a common function for social and speech perception: implications for the emergence of autism. *Neurosci. Biobehav. Rev.* 32, 123–142
- 10 Atmaca, M. *et al.* (2007) Volumetric MRI study of key brain regions implicated in obsessive-compulsive disorder. *Prog. Neuropsychopharmacol. Biol. Psychiatry* 31, 46–52
- 11 Whiteside, S.P. *et al.* (2004) A meta-analysis of functional neuroimaging in obsessive-compulsive disorder. *Psychiatry Res.* 132, 69–79
- 12 Bailey, A. *et al.* (1998) A clinicopathological study of autism. *Brain* 121, 889–905
- 13 Kemper, T.L. and Bauman, M.L. (1993) The contribution of neuropathologic studies to the understanding of autism. *Neurol. Clin.* 11, 175–187
- 14 Giedd, J.N. *et al.* (1999) Brain development during childhood and adolescence: a longitudinal MRI study. *Nat. Neurosci.* 2, 861–863
- 15 Brambilla, P. *et al.* (2003) Brain anatomy and development in autism: review of structural MRI studies. *Brain Res. Bull.* 61, 557–569
- 16 Courchesne, E. *et al.* (2003) Evidence of brain overgrowth in the first year of life in autism. *JAMA* 290, 337–344
- 17 Dawson, G. *et al.* (2007) Rate of head growth decelerates and symptoms worsen in the second year of life in autism. *Biol. Psychiatry* 61, 458–464
- 18 Dementieva, Y.A. *et al.* (2005) Accelerated head growth in early development of individuals with autism. *Pediatr. Neurol.* 32, 102–108
- 19 Hazlett, H.C. *et al.* (2005) Magnetic resonance imaging and head circumference study of brain size in autism: birth through age 2 years. *Arch. Gen. Psychiatry* 62, 1366–1376
- 20 Courchesne, E. *et al.* (2001) Unusual brain growth patterns in early life in patients with autistic disorder: an MRI study. *Neurology* 57, 245–254
- 21 Sparks, B.F. *et al.* (2002) Brain structural abnormalities in young children with autism spectrum disorder. *Neurology* 59, 184–192
- 22 Aylward, E.H. *et al.* (2002) Effects of age on brain volume and head circumference in autism. *Neurology* 59, 175–183
- 23 Herbert, M.R. *et al.* (2003) Dissociations of cerebral cortex, subcortical and cerebral white matter volumes in autistic boys. *Brain* 126, 1182–1192
- 24 Palmen, S.J. *et al.* (2005) Increased gray-matter volume in medication-naive high-functioning children with autism spectrum disorder. *Psychol. Med.* 35, 561–570
- 25 Schumann, C.M. *et al.* (2004) The amygdala is enlarged in children but not adolescents with autism; the hippocampus is enlarged at all ages. *J. Neurosci.* 24, 6392–6401
- 26 Piven, J. *et al.* (1996) Regional brain enlargement in autism: a magnetic resonance imaging study. *J. Am. Acad. Child Adolesc. Psychiatry* 35, 530–536
- 27 Lotspeich, L.J. *et al.* (2004) Investigation of neuroanatomical differences between autism and Asperger syndrome. *Arch. Gen. Psychiatry* 61, 291–298
- 28 Hazlett, H.C. *et al.* (2006) Cortical gray and white brain tissue volume in adolescents and adults with autism. *Biol. Psychiatry* 59, 1–6
- 29 Barnea-Goraly, N. *et al.* (2004) White matter structure in autism: preliminary evidence from diffusion tensor imaging. *Biol. Psychiatry* 55, 323–326
- 30 Keller, T.A. *et al.* (2007) A developmental study of the structural integrity of white matter in autism. *Neuroreport* 18, 23–27
- 31 Alexander, A.L. *et al.* (2007) Diffusion tensor imaging of the corpus callosum in autism. *Neuroimage* 34, 61–73
- 32 Ben Bashat, D. *et al.* (2007) Accelerated maturation of white matter in young children with autism: a high b value DWI study. *Neuroimage* 37, 40–47
- 33 Carper, R.A. *et al.* (2002) Cerebral lobes in autism: early hyperplasia and abnormal age effects. *Neuroimage* 16, 1038–1051
- 34 Herbert, M.R. *et al.* (2004) Localization of white matter volume increase in autism and developmental language disorder. *Ann. Neurol.* 55, 530–540
- 35 Carper, R.A. and Courchesne, E. (2005) Localized enlargement of the frontal cortex in early autism. *Biol. Psychiatry* 57, 126–133
- 36 Girgis, R.R. *et al.* (2007) Volumetric alterations of the orbitofrontal cortex in autism. *Prog. Neuropsychopharmacol. Biol. Psychiatry* 31, 41–45
- 37 Hardan, A.Y. *et al.* (2006) Magnetic resonance imaging study of the orbitofrontal cortex in autism. *J. Child Neurol.* 21, 866–871
- 38 Levitt, J.G. *et al.* (2003) Cortical sulcal maps in autism. *Cereb. Cortex* 13, 728–735
- 39 Nordahl, C.W. *et al.* (2007) Cortical folding abnormalities in autism revealed by surface-based morphometry. *J. Neurosci.* 27, 11725–11735
- 40 Hardan, A.Y. *et al.* (2006) An MRI study of increased cortical thickness in autism. *Am. J. Psychiatry* 163, 1290–1292
- 41 Hadjikhani, N. *et al.* (2005) Anatomical differences in the mirror neuron system and social cognition network in autism. *Cereb. Cortex* 16, 1276–1282
- 42 Buxhoeveden, D.P. *et al.* (2006) Reduced minicolumns in the frontal cortex of patients with autism. *Neuropathol. Appl. Neurobiol.* 32, 483–491
- 43 Casanova, M.F. *et al.* (2002) Minicolumnar pathology in autism. *Neurology* 58, 428–432
- 44 Casanova, M.F. *et al.* (2006) Minicolumnar abnormalities in autism. *Acta Neuropathol.* 112, 287–303
- 45 Minshew, N.J. *et al.* (2005) Neurologic aspects of autism. In *Handbook of Autism and Pervasive Developmental Disorders* (Vol. 1) (Volkmar, F.R. *et al.*, eds), In pp. 473–514, John Wiley & Sons
- 46 Hardan, A.Y. *et al.* (2001) Posterior fossa magnetic resonance imaging in autism. *J. Am. Acad. Child Adolesc. Psychiatry* 40, 666–672
- 47 Kaufmann, W.E. *et al.* (2003) Specificity of cerebellar vermian abnormalities in autism: a quantitative magnetic resonance imaging study. *J. Child Neurol.* 18, 463–470
- 48 Courchesne, E. *et al.* (1994) Cerebellar hypoplasia and hyperplasia in infantile autism. *Lancet* 343, 63–64
- 49 Piven, J. *et al.* (1997) An MRI study of autism: the cerebellum revisited. *Neurology* 49, 546–551
- 50 Okugawa, G. *et al.* (2003) Smaller cerebellar vermis but not hemisphere volumes in patients with chronic schizophrenia. *Am. J. Psychiatry* 160, 1614–1617
- 51 Palmen, S.J. *et al.* (2004) Neuropathological findings in autism. *Brain* 127, 2572–2583
- 52 Ritvo, E.R. *et al.* (1986) Lower Purkinje cell counts in the cerebella of four autistic subjects: initial findings of the UCLA-NSAC Autopsy Research Report. *Am. J. Psychiatry* 143, 862–866
- 53 Yip, J. *et al.* (2007) Decreased GAD67 mRNA levels in cerebellar Purkinje cells in autism: pathophysiological implications. *Acta Neuropathol.* 113, 559–568
- 54 Juranek, J. *et al.* (2006) Association between amygdala volume and anxiety level: magnetic resonance imaging (MRI) study in autistic children. *J. Child Neurol.* 21, 1051–1058
- 55 Munson, J. *et al.* (2006) Amygdalar volume and behavioral development in autism. *Arch. Gen. Psychiatry* 63, 686–693
- 56 Haznedar, M.M. *et al.* (2000) Limbic circuitry in patients with autism spectrum disorders studied with positron emission tomography and magnetic resonance imaging. *Am. J. Psychiatry* 157, 1994–2001
- 57 Aylward, E.H. *et al.* (1999) MRI volumes of amygdala and hippocampus in non-mentally retarded autistic adolescents and adults. *Neurology* 53, 2145–2150
- 58 Naciewicz, B.M. *et al.* (2006) Amygdala volume and nonverbal social impairment in adolescent and adult males with autism. *Arch. Gen. Psychiatry* 63, 1417–1428
- 59 Pierce, K. *et al.* (2001) Face processing occurs outside the fusiform ‘face area’ in autism: evidence from functional MRI. *Brain* 124, 2059–2073
- 60 Schumann, C.M. and Amaral, D.G. (2006) Stereological analysis of amygdala neuron number in autism. *J. Neurosci.* 26, 7674–7679
- 61 Hardan, A.Y. *et al.* (2006) Abnormal brain size effect on the thalamus in autism. *Psychiatry Res.* 147, 145–151
- 62 Haznedar, M.M. *et al.* (2006) Volumetric analysis and three-dimensional glucose metabolic mapping of the striatum and thalamus in patients with autism spectrum disorders. *Am. J. Psychiatry* 163, 1252–1263
- 63 Tsatsanis, K.D. *et al.* (2003) Reduced thalamic volume in high-functioning individuals with autism. *Biol. Psychiatry* 53, 121–129
- 64 Hollander, E. *et al.* (2005) Striatal volume on magnetic resonance imaging and repetitive behaviors in autism. *Biol. Psychiatry* 58, 226–232
- 65 Sears, L.L. *et al.* (1999) An MRI study of the basal ganglia in autism. *Prog. Neuropsychopharmacol. Biol. Psychiatry* 23, 613–624

- 66 Hardan, A.Y. *et al.* (2003) Motor performance and anatomic magnetic resonance imaging (MRI) of the basal ganglia in autism. *J. Child Neurol.* 18, 317–324
- 67 Langen, M. *et al.* (2007) Caudate nucleus is enlarged in high-functioning medication-naïve subjects with autism. *Biol. Psychiatry* 62, 262–266
- 68 Dager, S.R. *et al.* (2007) Shape mapping of the hippocampus in young children with autism spectrum disorder. *AJNR Am. J. Neuroradiol.* 28, 672–677
- 69 Nicolson, R. *et al.* (2006) Detection and mapping of hippocampal abnormalities in autism. *Psychiatry Res.* 148, 11–21
- 70 DeFelipe, J. (2005) Reflections on the structure of the cortical minicolumn. In *Neocortical Modularity and the Cell Minicolumn* (Casanova, M., ed.), pp. 57–92, Nova Science Publishers
- 71 Jones, E.G. (2000) Microcolumns in the cerebral cortex. *Proc. Natl. Acad. Sci. U. S. A.* 97, 5019–5021
- 72 Rockland, K.S. and Ichinohe, N. (2004) Some thoughts on cortical minicolumns. *Exp. Brain Res.* 158, 265–277
- 73 Lübke, J. and Feldmeyer, D. (2007) Excitatory signal flow and connectivity in a cortical column: focus on barrel cortex. *Brain Struct. Funct.* 212, 3–17
- 74 Mountcastle, V.B. (1997) The columnar organization of the neocortex. *Brain* 120, 701–722
- 75 Rakic, P. (1988) Specification of cerebral cortical areas. *Science* 241, 170–176
- 76 Conel, J. (1939) *The Postnatal Development of the Human Cerebral Cortex.* Harvard University Press

Endeavour

The quarterly magazine for the history and philosophy of science.

You can access *Endeavour* online on ScienceDirect, where you'll find book reviews, editorial comment and a collection of beautifully illustrated articles on the history of science.

Featuring:

Information revolution: William Chambers, the publishing pioneer by A. Fyfe

Does history count? by K. Anderson

Waking up to shell shock: psychiatry in the US military during World War II by H. Pols

Deserts on the sea floor: Edward Forbes and his azoic hypothesis for a lifeless deep ocean by T.R. Anderson and T. Rice

'Higher, always higher': technology, the military and aviation medicine during the age of the two world wars by C. Kehrt

Bully for *Apatosaurus* by P. Brinkman

Coming soon:

Environmentalism out of the Industrial Revolution by C. Macleod

Pandemic in print: the spread of influenza in the Fin de Siècle by J. Mussell

Earthquake theories in the early modern period by F. Willmoth

Science in fiction - attempts to make a science out of literary criticism by J. Adams

The birth of botanical *Drosophila* by S. Leonelli

And much, much more...

Endeavour is available on ScienceDirect, www.sciencedirect.com